

## CLINICAL PRACTICE GUIDELINES

# Bone sarcomas: ESMO–PaedCan–EURACAN Clinical Practice Guidelines for diagnosis, treatment and follow-up<sup>†</sup>

P. G. Casali<sup>‡1</sup>, S. Bielack<sup>‡2</sup>, N. Abecassis<sup>3</sup>, H.T. Aro<sup>4</sup>, S. Bauer<sup>5</sup>, R. Biagini<sup>6</sup>, S. Bonvalot<sup>7</sup>, I. Boukovinas<sup>8</sup>, J. V. M. G. Bovee<sup>9</sup>, B. Brennan<sup>10</sup>, T. Brodowicz<sup>11</sup>, J. M. Broto<sup>12</sup>, L. Brugières<sup>13</sup>, A. Buonadonna<sup>14</sup>, E. De Álava<sup>15</sup>, A. P. Dei Tos<sup>16</sup>, X. G. Del Muro<sup>17</sup>, P. Dileo<sup>18</sup>, C. Dhooge<sup>19</sup>, M. Eriksson<sup>20</sup>, F. Fagioli<sup>21</sup>, A. Fedenko<sup>22</sup>, V. Ferraresi<sup>6</sup>, A. Ferrari<sup>23</sup>, S. Ferrari<sup>24</sup>, A. M. Frezza<sup>25</sup>, N. Gaspar<sup>13</sup>, S. Gasperoni<sup>26</sup>, H. Gelderblom<sup>27</sup>, T. Gil<sup>28</sup>, G. Grignani<sup>29</sup>, A. Gronchi<sup>1</sup>, R. L. Haas<sup>30</sup>, B. Hassan<sup>31</sup>, S. Hecker-Nolting<sup>2</sup>, P. Hohenberger<sup>32</sup>, R. Issels<sup>33</sup>, H. Joensuu<sup>34</sup>, R. L. Jones<sup>35</sup>, I. Judson<sup>36</sup>, P. Jutte<sup>37</sup>, S. Kaal<sup>38</sup>, L. Kager<sup>39</sup>, B. Kasper<sup>32</sup>, K. Kopeckova<sup>40</sup>, D. A. Krákorová<sup>41</sup>, R. Ladenstein<sup>39</sup>, A. Le Cesne<sup>13</sup>, I. Lugowska<sup>42</sup>, O. Merimsky<sup>43</sup>, M. Montemurro<sup>44</sup>, B. Morland<sup>45</sup>, M. A. Pantaleo<sup>46</sup>, R. Piana<sup>21</sup>, P. Picci<sup>24</sup>, S. Piperno-Neumann<sup>7</sup>, A. L. Pousa<sup>47</sup>, P. Reichardt<sup>48</sup>, M. H. Robinson<sup>49</sup>, P. Rutkowski<sup>42</sup>, A. A. Safwat<sup>50</sup>, P. Schöffski<sup>51</sup>, S. Sleijfer<sup>52</sup>, S. Stacchiotti<sup>25</sup>, S. J. Strauss<sup>18</sup>, K. Sundby Hall<sup>53</sup>, M. Unk<sup>54</sup>, F. Van Coevorden<sup>55</sup>, W.T.A. van der Graaf<sup>35,38,55</sup>, J. Whelan<sup>18</sup>, E. Wardelmann<sup>56</sup>, O. Zaikova<sup>57</sup> & J. Y. Blay<sup>58</sup>, on behalf of the ESMO Guidelines Committee, PaedCan and ERN EURACAN<sup>\*</sup>

<sup>1</sup>Fondazione IRCCS Istituto Nazionale dei Tumori, Milan and University of Milan, Milan, Italy; <sup>2</sup>Klinikum Stuttgart-Olgahospital, Stuttgart, Germany; <sup>3</sup>Instituto Portugues de Oncologia de Lisboa Francisco Gentil EPE, Lisbon, Portugal; <sup>4</sup>Turku University Hospital (Turun Yliopistollinen Keskussairaala), Turku, Finland; <sup>5</sup>University Hospital Essen, Essen, Germany; <sup>6</sup>Department of Oncological Orthopedics, Musculoskeletal Tissue Bank, IFO, Regina Elena National Cancer Institute, Rome, Italy; <sup>7</sup>Institut Curie, Paris, France; <sup>8</sup>Bioclinic Thessaloniki, Thessaloniki, Greece; <sup>9</sup>Department of Pathology, Leiden University Medical Center, Leiden, The Netherlands; <sup>10</sup>Royal Manchester Children's Hospital, Manchester, UK; <sup>11</sup>Vienna General Hospital (AKH), Medizinische Universität Wien, Vienna, Austria; <sup>12</sup>Hospital Universitario Virgen del Rocío-CIBERONC, Seville, Spain; <sup>13</sup>Gustave Roussy Cancer Campus, Villejuif, France; <sup>14</sup>Centro di Riferimento Oncologico di Aviano, Aviano; <sup>15</sup>Institute of Biomedicine of Seville (IBiS), Virgen del Rocío University Hospital /CSIC/University of Seville/CIBERONC, Seville, Spain; <sup>16</sup>Ospedale Regionale di Treviso "S.Maria di Cà Foncello", Treviso, Italy; <sup>17</sup>Integrated Unit ICO Hospitalet, HUB, Barcelona, Spain; <sup>18</sup>Sarcoma Unit, University College London Hospitals NHS Trust, London, UK; <sup>19</sup>Ghent University Hospital (Pediatric Hematology-Oncology & Stem Cell Transplantation), Ghent, Belgium; <sup>20</sup>Skane University Hospital-Lund, Lund, Sweden; <sup>21</sup>Pediatric Onco-Hematology, Stem Cell Transplantation and Cellular Therapy Division, Regina Margherita Children's Hospital, University of Turin, Turin, Italy; <sup>22</sup>N. N. Blokhin Russian Cancer Research Center, Moscow, Russian Federation; <sup>23</sup>Pediatric Oncology Unit, Fondazione IRCCS Istituto Nazionale dei Tumori, Milan; <sup>24</sup>Istituto Ortopedico Rizzoli, Bologna; <sup>25</sup>Fondazione Istituto di Ricovero e Cura a Carattere Scientifico, Istituto Nazionale dei Tumori, Milan, Italy; <sup>26</sup>Azienda Ospedaliera Universitaria Careggi Firenze, Florence, Italy; <sup>27</sup>Department of Medical Oncology, Leiden University Medical Centre, Leiden, The Netherlands; <sup>28</sup>Institut Jules Bordet, Brussels, Belgium; <sup>29</sup>Candiolo Cancer Institute, FPO IRCCS, Candiolo, Italy; <sup>30</sup>Department of Radiotherapy, The Netherlands Cancer Institute, Amsterdam and Department of Radiotherapy, Leiden University Medical Centre, Leiden, The Netherlands; <sup>31</sup>Oxford University Hospitals NHS Foundation Trust, Oxford, UK; <sup>32</sup>Mannheim University Medical Center, Mannheim; <sup>33</sup>Department of Medicine III, University Hospital Ludwig-Maximilians-University Munich, Munich, Germany; <sup>34</sup>Helsinki University Central Hospital (HUCH), Helsinki, Finland; <sup>35</sup>Royal Marsden Hospital, London; <sup>36</sup>The Institute of Cancer Research, London, UK; <sup>37</sup>University Medical Center Groningen, Groningen; <sup>38</sup>Radboud University Medical Center, Nijmegen, The Netherlands; <sup>39</sup>St. Anna Children's Hospital & Children's Cancer Research Institute, Medical University Vienna, Vienna, Austria; <sup>40</sup>University Hospital Motol, Prague; <sup>41</sup>Masaryk Memorial Cancer Institute, Brno, Czech Republic; <sup>42</sup>Maria Skłodowska Curie Institute-Oncology Centre, Warsaw, Poland; <sup>43</sup>Tel Aviv Sourasky Medical Center (Ichilov), Tel Aviv, Israel; <sup>44</sup>Medical Oncology University Hospital of Lausanne, Lausanne, Switzerland; <sup>45</sup>Birmingham Women's and Children's NHS Foundation Trust, Birmingham, UK; <sup>46</sup>Azienda Ospedaliera, Universitaria, Policlinico S Orsola-Malpighi Università di Bologna, Bologna, Italy; <sup>47</sup>Fundacio de Gestio Sanitaria de L'Hospital de la Santa Creu I Sant Pau, Barcelona, Spain; <sup>48</sup>Helios Klinikum Berlin Buch, Berlin, Germany; <sup>49</sup>CRCC Department of Clinical Oncology, Weston Park Hospital NHS Trust, Sheffield, UK; <sup>50</sup>Aarhus University Hospital, Aarhus, Finland; <sup>51</sup>Department of General Medical Oncology, Leuven Cancer Institute, University Hospitals Leuven, Leuven, Belgium; <sup>52</sup>Department of Medical Oncology, Erasmus MC Cancer Institute, Rotterdam, The Netherlands; <sup>53</sup>Department of Oncology, Oslo University Hospital, The Norwegian Radium Hospital, Oslo, Norway; <sup>54</sup>Institute of Oncology of Ljubljana, Ljubljana, Slovenia; <sup>55</sup>Netherlands Cancer Institute Antoni van Leeuwenhoek, Amsterdam, The Netherlands; <sup>56</sup>Gerhard-Domagk-Institut für Pathologie, Universitätsklinikum Münster, Münster, Germany; <sup>57</sup>Norwegian Radium Hospital, Oslo University Hospital, Oslo, Norway; <sup>58</sup>Centre Leon Bernard and UCBL1, Lyon, France

\*Correspondence to: ESMO Guidelines Committee, ESMO Head Office, Via Ginevra 4, 6900 Lugano, Switzerland. E-mail: clinicalguidelines@esmo.org

<sup>†</sup>Approved by the ESMO Guidelines Committee, PaedCan and EURACAN: August 2018.

<sup>‡</sup>Contributed equally.

## Incidence and epidemiology

Primary bone tumours are rare, accounting for < 0.2% of malignant neoplasms registered in the EURO CARE (European Cancer Registry based study on survival and care of cancer patients) database [1]. Different bone tumour subtypes have distinct patterns of incidence, and each has no more than 0.3 incident cases per 100 000 per year. Osteosarcoma (OS) and Ewing sarcoma (ES) have a relatively high incidence in the second decade of life, whereas chondrosarcoma (CS) is more common in older age [2–4].

OS is the first primary cancer of bone (incidence: 0.3 per 100 000 per year). The incidence is higher in adolescents (0.8–1.1 per 100 000 per year at age 15–19 years) [2–3]. The male to female ratio is 1.4:1. Most OSs of younger patients arise in an extremity, while the proportion of axial tumour sites increases with age. Risk factors for the occurrence of OS include previous radiotherapy (RT), Paget disease of bone and germline genetic abnormalities associated with Li–Fraumeni syndrome, Werner syndrome, Rothmund–Thomson syndrome, Bloom syndrome and hereditary retinoblastoma [5].

CS is the most frequent bone sarcoma of adulthood. The incidence is ~ 0.2 per 100 000 per year, with a median age at diagnosis between 30 and 60 years. No gender predominance has been reported [2–4, 6].

ES is the third most common primary malignant bone tumour. It occurs most frequently in children and adolescents, but is also seen in adults. Median age at diagnosis is 15 years and there is a male predominance (1.5:1). In white Caucasians > 25 years old, ES has an incidence of 0.3 per 100 000 per year [1–4], and it is even rarer in the African and Asian population. The genetic basis for the difference between ethnic groups has been recently linked to a common genomic germline variant, which extends a microsatellite, thereby facilitating the binding of the EWSR1–FLI1 chimeric protein to the *EGR2* gene locus, leading to higher expression of the transcription factor early growth response 2 (*EGR2*) and increased susceptibility to ES [7]. The most common ES primary sites are the extremity bones (50% of all cases), followed by pelvis, ribs and vertebra. However, any bone can potentially be affected and a soft tissue origin is also possible, especially in adults (30% of cases).

Chordomas are even rarer compared with other subtypes, with an incidence of ~ 0.5 per million per year [1–4].

High-grade spindle/pleomorphic sarcomas of bone are a heterogeneous group of primary malignant bone tumours that do not fulfil the histological criteria for a diagnosis of OS, CS or ES [8].

Giant cell tumour (GCT) of bone is a benign, locally aggressive and rarely metastatic intramedullary bone tumour composed of mononuclear cells and osteoclast-like multinucleated giant cells, with a variable and unpredictable potential for aggressive growth. It represents ~ 5% of primary bone tumours, with an incidence of approximately 1 per million per year [9].

## Diagnosis and pathology/molecular biology

A general diagnostic strategy for bone sarcomas is shown in Figure 1. The medical history should focus on characteristic symptoms such as duration, intensity and timing of pain. The presence of persistent non-mechanical bone pain, predominantly

at night, should prompt a radiological assessment. Swelling and functional impairment can be present if the tumour has progressed through the cortex and distended the periosteum, but they are often later signs. The differential diagnosis of a bone sarcoma includes osteomyelitis, benign tumours and bone metastases, all of which outnumber primary bone sarcomas [10–12]. The diagnosis can be strongly oriented by patient age. For patients < 5 years old, a destructive bone lesion could be interpreted predominantly as either metastatic neuroblastoma or Langerhans cell histiocytosis (LCH). For patients aged ≥ 5 years old, the likelihood of a primary bone sarcoma is higher. In adult patients, after 40 years of age, bone metastases and myeloma are the most common diagnoses [12].

Conventional radiograph in two planes is the first radiological investigation. When the diagnosis of malignancy cannot be excluded with certainty on radiographs, the next step should be magnetic resonance imaging (MRI) of the whole compartment with adjacent joints, which is regarded today as the best modality for local staging of extremity and pelvic tumours [13]. Computed tomography (CT) may provide additional information by allowing a better visualisation of calcifications, periosteal bone formation and cortical destruction. It is generally the imaging modality of choice of other primary sites.

All patients with a bone lesion that is likely to be a primary malignant bone tumour on a radiological basis should be referred to a bone sarcoma centre or to an institution belonging to a specialised sarcoma network [14–15]. Children and adolescents should be referred to centres which in addition provide age-specific expertise. The biopsy and the pathological diagnosis require expertise in the field and should be discussed in a multidisciplinary setting.

The biopsy of a suspected primary malignant bone tumour should be carried out at the reference centre for bone sarcomas, with a primary biopsy under the supervision of a surgical team who will carry out the definitive tumour resection or by a dedicated interventional radiologist [14–17]. In most patients, a core-needle biopsy, taken under imaging control, can be an appropriate alternative to open biopsy. Contamination of surrounding tissue should be minimised, and adequate multiple sampling of representative areas must always be provided. The biopsy approach and area of tumour to be sampled are pre-determined after multidisciplinary review of imaging. If osteomyelitis is a differential diagnosis, samples should be sent for microbiological culture. If required, an open biopsy should be carried out using a longitudinal incision. In aggressive and malignant tumours of bone, the biopsy tract and the channels through which drains have been placed must be considered to be potentially contaminated and must later be removed, together with the resection specimen, in an effort to minimise the risk of a local recurrence. Therefore, biopsy tracts should be clearly marked by means of a small incision or an ink tattoo to ensure that the location is recognised at the time of the definitive procedure. In case of spinal column involvement, laminectomy or decompression should be avoided unless necessary to relieve spinal cord compression, and tissue sampling must be carried out whenever a bone sarcoma is suspected.

Samples must be interpreted by an experienced bone sarcoma pathologist, in collaboration with the radiologist, and discussed in a multidisciplinary team. The request form should be

completed with all details that might be relevant for diagnosis, including patient's age, the site of the tumour, radiological findings, presence of multiple lesions, family history and preoperative treatments for surgical specimens.

With the increasing capability for accurate molecular diagnosis and next-generation sequencing (NGS) technologies, samples should be quickly submitted for pathological assessment. The collection of fresh frozen tissue is strongly encouraged, to enable molecular diagnostics. As an alternative, decalcification in ethylenediaminetetraacetic acid (EDTA) instead of methanoic acid can be considered. Tumour imprints (touch preparations) are used by some, but not all, expert institutions: they might be useful for tumour-specific translocation by fluorescent *in situ* hybridisation (FISH) in some institutions. Informed consent for tumour banking should be routinely sought as for all rare malignancies, enabling later analyses for research, depending on local regulations.

The nature of the bone specimen received for pathology reporting should be recorded, i.e. needle biopsy, curettage or excision (e.g. segmental resection, limb salvage amputation, or another complex resection, such as a hemipelvectomy). It is usually necessary to decalcify the bone tumour biopsy using specific standard operating procedures. The histological features of the tumour should be described and the tumour type (and subtype) specified according to the most recent version of the World Health Organization (WHO) classification [18, 19]. The results of relevant ancillary investigations (e.g. immunohistochemistry or molecular assessments) should be accurately recorded. Molecular diagnostic techniques currently available include FISH, reverse transcription-polymerase chain reaction (RT-PCR) and NGS technologies. Examples include translocation detection in ES and mesenchymal CS, isocitrate dehydrogenase (*IDH1* and *IDH2*) mutations in conventional CS and *MDM2* amplification in parosteal and intramedullary low-grade OS.

At the time of the resection of the primary tumour, the size of the tumour in the resected bone should be recorded (three-dimensional measurement in mm) [19, 20]. The pathology report should also describe the extent of local tumour spread, including involvement of specific anatomical soft tissue and bone compartments. It should be recorded whether the resection margins are either clear or infiltrated and the distance of tumour from the nearest resection margin measured (in mm). Photographs should be taken of the intact specimen and of the tumour slabs after sawing. A complete, representative slab of the tumour, usually in the longitudinal axis as guided by the radiological images, should be embedded in a grid manner for microscopy. This is especially relevant after neoadjuvant chemotherapy (ChT) to assess response. The tumour should be coded using Systematic Nomenclature of Medicine (SNOMED) or International Classification of Diseases for Oncology (ICD-O) codes.

### Staging and risk assessment

All new cases of bone tumours should be formally discussed in a multidisciplinary team at a bone sarcoma reference centre with the radiologist, the pathologist, the surgeon, the radiation

oncologist and the medical and/or paediatric oncologist. The output of the multidisciplinary discussion must be recorded.

Several staging systems for bone tumours are in use [20–22]. However, none of them is perfect or generally accepted. Tumour burden (volume) and the presence of detectable metastases are the two main factors that are taken into consideration in the clinical staging of these diseases. General staging should be carried out to assess the extent of distant disease, including bone scintigraphy, chest radiographs and CT [23]. Whole-body MRI and positron emission tomography (PET)-CT or PET-MRI are increasingly used for staging (including detection of 'skip' bone lesions) [24]. Additional appropriate imaging studies and biopsies can be taken from suspicious sites, as the exact staging of the disease has an impact on treatment and outcome.

No specific laboratory tests for the diagnosis of bone sarcoma are routinely available. Baseline serum analysis in ES and OS should include alkaline phosphatase (AP) and lactate dehydrogenase (LDH), given their proven prognostic value [25–27]. Prognostic features also include clinical presentation: a pathological fracture may lead to the dissemination of tumour cells into surrounding tissues and increase the risk of local recurrence. In cases of fracture, internal fixation is contraindicated as it disseminates the tumour further into both bone and soft tissues and increases the risk of local recurrence. External splintage is recommended.

ChT can result in renal, cardiac and auditory dysfunction. Before starting the treatment, baseline renal function testing, assessment of cardiac function [left ventricular ejection fraction (LVEF)] and audiogram (in the case of platinum derivatives) should be carried out. Sperm storage is recommended for male patients of reproductive age. For female patients, a fertility physician is routinely consulted about potential ovarian tissue sampling and cryopreservation in some but not all countries, reflecting a variability of healthcare policies across nations.

### Treatment (locoregional and advanced disease)

Given the rarity of the disease and the complexity of management, the accepted standard for bone sarcomas is treatment at reference centres and/or within reference networks able to provide access to the full spectrum of care and age-specific expertise [III, A]. In these centres/networks, therapy is usually given within either the framework of prospective, often collaborative, clinical studies or established treatment protocols. In the case of high-grade OS, ES or pleomorphic sarcoma, following biopsy proven-diagnosis, primary ChT is generally recommended by expert centres.

### Osteosarcoma

OS usually arises in the metaphysis of a long bone, most commonly around the knee in children and adolescents. Involvement of the axial skeleton and craniofacial bones is primarily observed in older patients. High-grade OS frequently metastasises, the lung being the most frequent metastatic site by far, followed by distant bones.

Conventional OS is always high-grade. Parosteal OSs are low-grade malignancies, although they may increase in size and invade the medulla of bone, and transform to high-grade sarcoma, whereas periosteal OS is an intermediate-grade chondroblastic OS, sometimes difficult to distinguish from high-grade surface OS. Adverse prognostic or predictive factors for conventional OS include detectable primary metastases, axial or proximal extremity tumour site, large tumour size, elevated serum AP or LDH and older age [III, B] [25, 26]. As mentioned above, staging should include local imaging studies, specifically plain radiographs and MRI of the whole affected extremity [III, A].

Curative treatment of high-grade OS consists of ChT and surgery [II, A]. Compared with surgery alone, multimodal ChT treatment of high-grade localised OS increases disease-free survival probability from 10%–20% to > 60%. In general, ChT is administered before and after surgery, although a formal proof that giving ChT preoperatively improves survival is lacking. The extent of histological response to preoperative ChT predicts survival [25–27].

Low-grade parosteal OSs are malignancies with a lower metastatic potential and should be treated by surgery alone [IV, B]. Although ChT has been used for periosteal OSs, no benefit for ChT was shown in retrospective analyses [28–30], and its use is not routinely recommended in this setting [IV, D].

Surgery should be carried out by a surgical team familiar with the wide range of surgical reconstructive options. Paediatric and adolescent patients need to be treated by surgeons with great experience in the field of paediatric bone tumours, including age-specific reconstruction challenges, such as the reconstruction of growing bones. The goal of surgery is to safely remove the tumour and yet preserve as much function as possible, striving to obtain microscopically clear surgical margins [27]. Most patients should be considered candidates for limb salvage. Either intralesional or marginal margins increase the local relapse rate, which is associated with reduced overall survival. Thus, clear margins are the first goal of surgery [III, B]. Areas where there is suspicion of close margins should be marked on the surgical specimen sent to pathology.

Pathological fracture does not necessarily necessitate an amputation. In chemosensitive tumours, primary neoadjuvant ChT can be used with the expectation that it will allow the fracture haematoma to contract and allow subsequent resection of the tumour and the involved soft tissues [31].

Doxorubicin, cisplatin, high-dose methotrexate (HD-MTX) and ifosfamide have antitumour activity in OS [I, A] [32–35]. The MAP (doxorubicin/cisplatin/HD-MTX) regimen is most frequently used as the basis of treatment in children and young adult patients [30]; however, HD-MTX can be difficult to manage in adults. In patients aged > 40, regimens combining doxorubicin, cisplatin and ifosfamide without HD-MTX can also be used in these patients [III, B] [33–36]. These drugs should be administered with adequate supportive care by experienced paediatric oncologists or medical oncologists at reference institutions with appropriate infrastructure and a multidisciplinary treatment approach. Most current protocols include a period of preoperative ChT, to facilitate local surgical treatment and to allow the assessment of tumour response [32–41]. The EURAMOS 1 prospective trial aimed to establish whether PEGylated

interferon alpha-2b (PEG-IFN $\alpha$ -2b), in addition to standard MAP ChT given postoperatively, could improve outcome in patients with good histological response to preoperative MAP. The results showed that many patients failed to start and complete interferon treatment, and there was no significant overall survival advantage [I, C] [34, 35]. The study also evaluated if altering postoperative ChT in poor responders to preoperative systemic therapy might have any impact on outcome, and, again, no survival benefit was proven. In case of poor pathological response to the preoperative MAP regimen, the postoperative addition of ifosfamide and etoposide to MAP failed to improve the survival and increased the risk of secondary malignancy compared with those patients treated with the MAP regimen only [I, C] [36]. Whenever possible, patients with OS should receive ChT in the context of prospective studies.

Innate immune-modulation has been attempted in OS with other agents, in particular muramyl tripeptide. As described above, the use of interferon failed to show a survival advantage in patients with a good histological response to an MAP-preoperative regimen. Muramyl tripeptide added to postoperative ChT was associated with a significant advantage in overall survival and a non-significant trend in event-free survival in one large randomised trial [II, C] [41]. Muramyl tripeptide has been approved in Europe for patients < 30 years of age with completely resected localised OS, but it is not reimbursed in all European countries. There is no consensus in the sarcoma community on the use of this drug, due to weaknesses in the data from the only trial currently available [41, 42]. Further studies are needed to identify any subgroup of patients who could benefit from immune modifying agents.

Dynamic MRI is reliable for evaluation of changes in tumour vascularity and to give additional information on tumour response to primary ChT [43, 44]. The value of diffusion MRI is currently under evaluation [44].

The multimodal treatment principles detailed above were generated in children, adolescents and young adults with high-grade central OS, but also relate to adults [III, B]. Adult patients may require tailored regimens, especially as far as HD-MTX is concerned, in particular for those aged > 40 years. Some studies have put a threshold of 25 years of age to remove HD-MTX from the induction regimen [45], while others included HD-MTX for older patients [46]. Doxorubicin plus cisplatin and/or ifosfamide are commonly used with age-adapted doses. Recently, the addition of zoledronic acid was tested in a randomised setting and failed to demonstrate an improvement in relapse-free or overall survival or histological response. Its use is, therefore, not recommended outside clinical trials [I, D].

In general, there is no indication for RT, but there are anatomical locations in which the possibility of complete surgical resection is limited. In these cases, after a multidisciplinary discussion, RT may be an option to try to extend the progression-free interval. This must be discussed in a multidisciplinary team beforehand and with the patient, and it should be made clear at the time of surgery that the goal is not an R0 resection (excision whose margins are clear of tumour cells) [V, C]. New RT techniques (e.g. proton and carbon ion beam RT) should be considered, particularly for unresectable primary tumours [47].

Primary metastatic OS patients are treated with a curative intent following the same principles of non-metastatic OSs [48]. In fact, there are subsets of patients who can have a very similar prognosis to that of localised disease, provided surgical removal of all known metastatic deposits is achievable [III, B] [49]. Approximately 25% of all patients with primary metastatic OS and > 40% of those who achieve a complete surgical remission may become long-term survivors.

High-grade craniofacial OS should be treated the same way as high-grade OS of other locations, although prospective evidence is lacking due to the absence of selective clinical studies in this patient population [IV, B]. PET-CT scanning may be advantageous for response assessment [50]. RT, preferably within clinical studies, can be proposed when complete surgery is not feasible [IV, B]. The value of proton/carbon ion beam RT in this setting is currently under study. Adjuvant RT follows the same recommendations as that for other sites (see above).

The management of recurrent OS needs to take into account the timing of recurrences/metastases, the number of metastases and the metastatic sites. CT scan can over- and under-estimate the number of pulmonary metastases, but the recent results have improved with spiral CT. The treatment of recurrent OS is primarily surgical in the case of isolated lung metastases. Complete removal of all metastases must be attempted [III, B], as the disease is otherwise almost universally fatal; more than a third of patients with a complete second surgical remission survive for > 5 years [51]. Even patients with subsequent recurrences may be cured as long as recurrences are resectable, and repeated thoracotomies are often warranted [51]. For lung metastases, stereotactic RT, radiofrequency ablation or cryotherapy might be used as alternative options in patients unfit for surgery [IV, B]. Some groups also consider radiofrequency ablation [52, 53] and stereotactic RT [54] to be potential alternative local treatment options for primary lung or bone metastases [52–54].

The role of second-line chemotherapy for recurrent OS is much less well defined. Treatment choice may take into account the prior disease-free interval, and often includes ifosfamide or cyclophosphamide, possibly in association with etoposide and/or carboplatin [III, B]; other active drugs and combinations include gemcitabine and docetaxel [IV, C], sorafenib [III, B] or regorafenib [II, B], as well as samarium ( $^{153}\text{Sm}$ ); the evidence for these drugs is limited and there are reimbursement constraints [55–60]. In the two largest reported series, the use of second-line ChT correlated with limited prolongation of survival in patients with inoperable metastatic recurrences, while a positive correlation in operable disease was observed in only one of the two [49, 50]. However, radiological responses and clinical benefit are commonly witnessed so that its use should be considered [IV, B].

RT may have a role in palliation. In general, despite second-line treatment, the prognosis of recurrent disease has remained poor, with a long-term post-relapse survival rate of < 20% [48, 49, 51].

### Ewing sarcoma

ES is a small, blue, round cell tumour, periodic acid-Schiff (PAS) positive and CD99 (MIC2)-positive. All ESs are high-grade tumours. They can arise both from bone, soft tissues or visceral sites, displaying the same behaviour in principle.

The definitive diagnosis is made by biopsy, providing sufficient material for conventional histology, immunohistochemistry, molecular pathology and biobanking. Molecular biology studies have shown that almost all of these tumours share a common *TET-ETS* gene rearrangement involving the *EWSR1* gene on chromosome 22 [61–64]. In most cases, this involves a reciprocal translocation  $t(11; 22)(q24; q12)$  [47], but  $t(21; 22)(q22; q12)$ , and others may also occur [ $t(7; 22)$ ,  $t(17; 22)$  and  $t(2; 22)$ ] [61–64]. In recent years, new small round cell sarcoma entities have been recognised, with novel translocations, among which BCL6 corepressor (*BCOR*)-rearranged sarcoma preferentially affects the bone. Other examples of recurrent molecular alterations found in these malignancies include EWS RNA binding protein 1—nuclear factor of activated T cells 2 (*EWSR1-NFATC2*), FUS RNA binding protein—nuclear factor of activated T cells 2 (*FUS-NFATC2*), capicua transcriptional repressor—forkhead box O4 (*CIC-FOXO4*) or capicua transcriptional repressor—double homeobox 4 (*CIC-DUX4*) translocations (see Table 1) [65–67].

Current investigations have shown that tumour biology and prognosis of these tumours, which are probably different nosological entities rather than molecular variants, actually differ from classical ES, making molecular testing mandatory. Currently, patients presenting with these variants are treated with Ewing-like regimens, although their best treatment and even their natural history are poorly known [65–67]. Inclusion in prospective registries is worthwhile [a European Reference Networks on adult rare solid cancers (EURACAN) sarcoma project is planned].

Although most ES tumours can be recognised with classical haematoxylin and eosin (H&E) stain, immunohistochemistry molecular confirmation is mandatory for the identification of the classical and distinct molecular subtypes as described above [III, A] [18, 62–67]. The laboratory should be enrolled in an external quality assurance programme. When frozen tissue is available, techniques that identify both fusion partners (i.e. RT-PCR or anchored, multiplex PCR-based, targeted NGS) are the techniques of choice. The latter can also be applied to non-decalcified or EDTA-decalcified, formalin-fixed paraffin-embedded (FFPE) tissue. FISH is a good choice when only FFPE tissue [or touch preparations (imprints)] are available. There are several commercial sources for *EWSR1* break-apart probes. Assays using *EWSR1* break-apart probes do not detect *EWS-FLI1* fusions, but only *EWSR1* rearrangements, which should not be a problem when interpreted in the appropriate clinical and pathological context. NGS should be considered when no typical translocation has been detected by conventional methods.

Bone marrow biopsies and aspirates (from sites distant to the primary or known metastatic lesions) may be considered in the staging, but several experts underline that there is a very low incidence of bone marrow metastases in localised disease if the PET scan is negative [68]. The added prognostic value of molecular positivity over light microscopic evaluation has not yet been proven [IV, C].

Between 20% and 25% of patients are diagnosed with metastatic disease [lung (10%); bone/bone marrow (10%); combinations or others (5%)] [69, 70]. Staging must be oriented to detect lung, bone and bone marrow metastases and should include biopsy in case of doubtful lesions. Multiple bone metastases confer a poorer outcome than lung/pleural metastases (< 20% compared

**Table 1. Personalised medicine synopsis table**

Biomarker	Method	Use	LoE	GoR
Genomic characterisation	PCR, FISH, NGS	Small round cell sarcoma	III	A

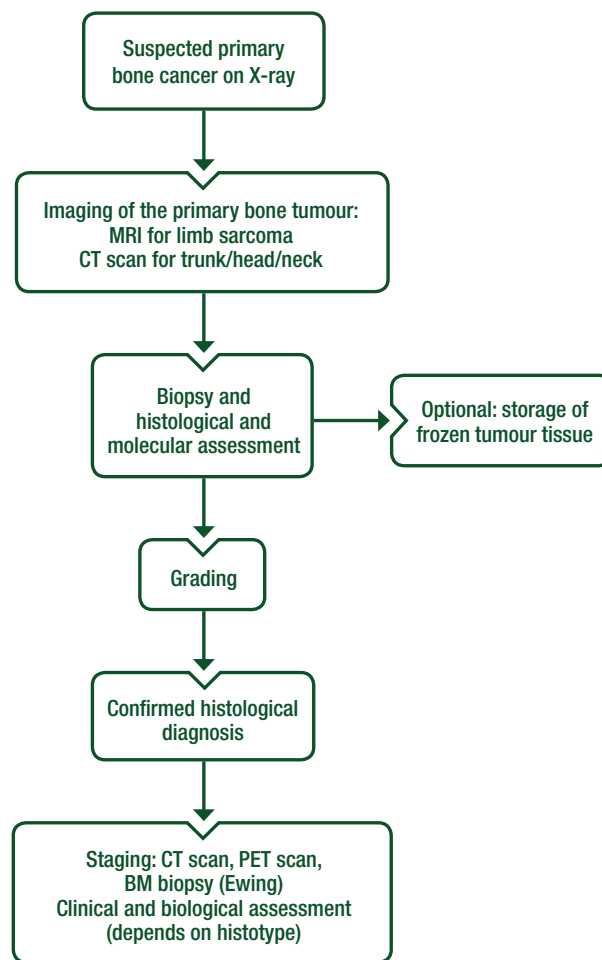
FISH, fluorescent *in situ* hybridisation; GoR, grade of recommendation; LoE, level of evidence; NGS, next-generation sequencing; PCR, polymerase chain reaction.

with 20%–40% 5-year survival). Other known adverse prognostic factors are large tumour size or volume, elevated serum LDH levels, non-extremity localisation and age > 15 years. A poor histological response to preoperative ChT and incomplete or no surgery for local therapy are further adverse prognostic factors [71–75]. The molecular structure of the EWSR1 fusion transcripts has not been shown to be of prognostic value with current treatment protocols. Genomic analysis with the assessment of copy number variation has been shown to be of prognostic value [75, 76]. In addition, *STAG2*, *TP53* and *CDKN2A* mutations confer poorer outcomes. With surgery or RT alone, i.e. without systemic treatments, 5-year survival was < 10%. With the currently recommended multimodal approaches including ChT, 5-year survival is ~ 60%–75% in localised and ~ 20%–40% in metastatic disease, respectively, depending on metastatic sites and burden (Figure 2).

Current trials employ 3–6 cycles of initial combination ChT after biopsy, followed by local therapy, and another 6–10 cycles of ChT, usually applied at 2- to 3-week intervals. Treatment duration is thus 10–12 months. Agents considered to be most active include doxorubicin, cyclophosphamide, ifosfamide, vincristine, dactinomycin and etoposide [77–81]. Almost all active protocols are based on five- to six-drug combinations of these substances [I, A]. Dose-dense regimens (with interval compression) were associated with a positive outcome in paediatric and adolescent (<18 years) patients in a prospective North American study [II, B] [82].

The use of high-dose ChT with escalated alkylating agent dose and blood stem cell rescue has attracted much attention in ES since the 1970s. Only recently have the results of randomised studies with busulfan and melphalan (BuMel) indicated that this approach results in a survival advantage for tightly defined and highly selected patients with poor response to induction ChT and/or tumour volume > 200 mL [I, B] [83, 84]. No such advantage was evident for patients presenting with pulmonary metastases [II, D] (Figure 2).

ES is a radiosensitive tumour at lower doses than OS. The goal of local therapy for the primary tumour is to ensure that the entire volume of tissue involved at diagnosis is treated. Complete surgical excision, where feasible, is regarded as the best modality of local control, given the higher risk of local recurrence when RT is used as the sole treatment of the primary tumour. Surgery must involve excision of all tissues originally involved with tumour (not just the tissue that is left after ChT shrinkage) or be supplemented by RT. RT alone (in the range of 45–60 Gy, depending on location) should be applied if complete surgical excision is impossible. Postoperative RT should be given in cases of inadequate surgical margins and discussed when histological response in the surgical specimen was poor (i.e. > 10% viable tumour cells) [IV,

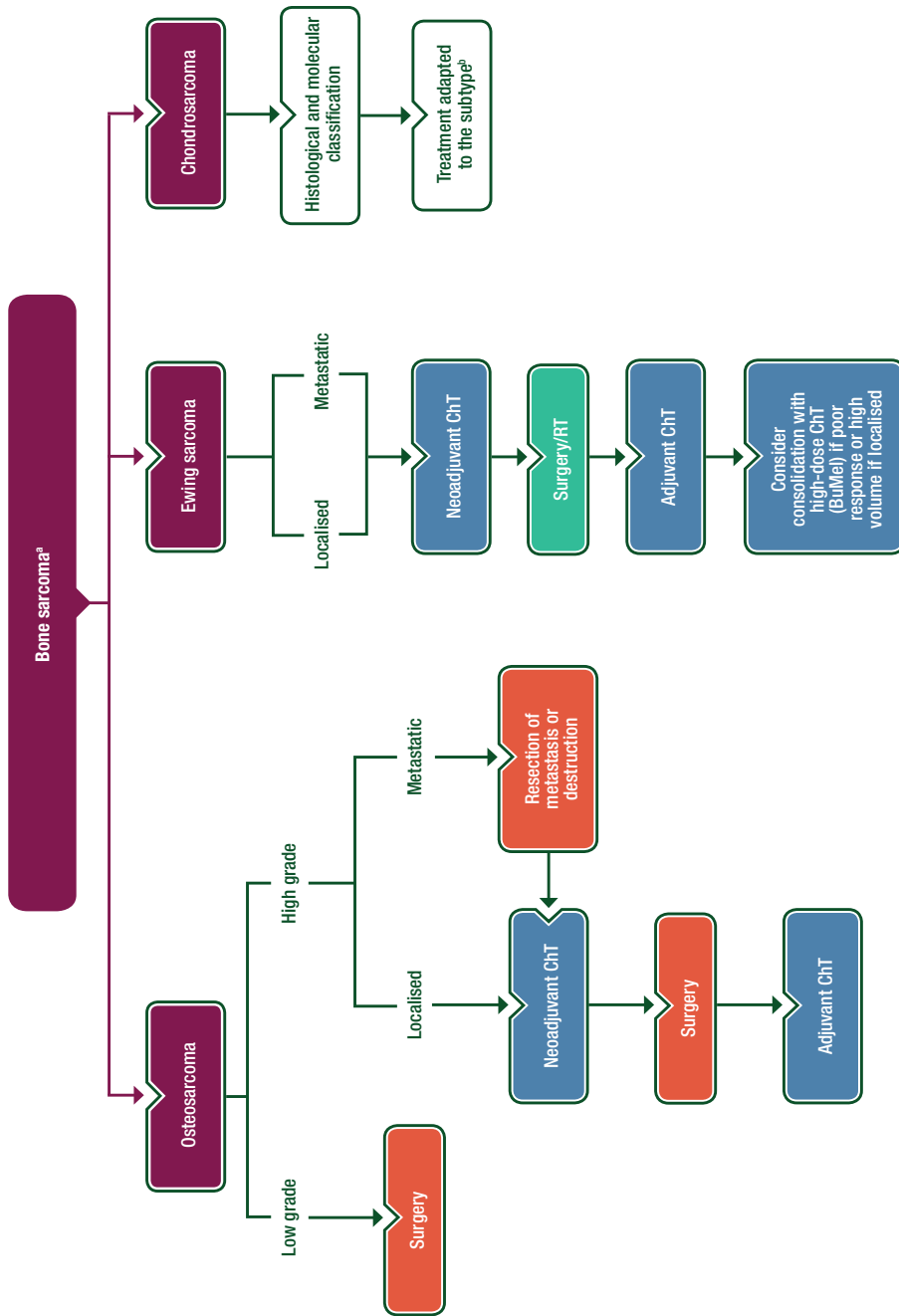


**Figure 1.** General diagnostic strategy for bone sarcomas. BM, bone marrow; CT, computed tomography; MRI, magnetic resonance imaging; PET, positron emission tomography.

B] [78]. The dose of postoperative RT is also 45–60 Gy, depending on margins, response and location. Intralesional surgery must be avoided, as there is no benefit when compared with RT alone [78]. Change in the size of the soft tissue mass is easily evaluated on MRI and is a good predictor of tumour response [43, 44]. Dynamic MRI is not as reliable as in OS [44], as remaining small tumour foci may not be detected. Sequential FDG-PET evaluation might be of additional value [85].

The treatment of adult patients follows the same principles as for children. However, tolerability of therapies in older patients needs to be taken into account when transferring treatment

Downloaded from https://academic.oup.com/annonc/article-abstract/29/Supplement\_4/iv84/5115250 by guest on 11 June 2019



**Figure 2.** General therapeutic strategy for the three most frequent bone sarcomas.  
<sup>a</sup>The treatment of primary bone sarcoma must be carried out in a bone sarcoma reference centre.  
<sup>b</sup>Depending on the chondrosarcoma subtype, treatment can be surgery, neoadjuvant and adjuvant ChT or RT. BuMeI, busulfan and melphalan; ChT, chemotherapy; RT, radiotherapy.

protocols conceived for children and patients of age  $\leq$  40–50 years. Treatment of patients with extraskelatal ES follows the same principles as for bone ES, thus incorporating ChT in all cases as well as postoperative RT in most cases, with the possible exception of superficial lesions. For extraskelatal ES, postoperative RT is generally used, with the possible exception of good prognosis, superficial ES.

Patients with metastases at diagnosis are treated with the same treatment approach as patients with localised disease but have a worse prognosis. In patients with lung metastases, whole-lung irradiation may confer a survival advantage [III, C] [86]. The role of surgical resection of residual metastases is less well defined.

For patients presenting with extra-pulmonary metastases, survival is even worse ( $<$  20%) [87]. ChT is similar to that for localised disease but responses are less durable. Treatment of the primary tumour is often appropriate, especially in the presence of responding metastatic disease. There is no formal evidence for high-dose ChT in this situation; therefore, practices diverge among centres. No randomised studies have been reported for this approach.

Recurrent ES, whether local or with distant metastases, is almost always fatal, even though further responses to ChT are frequent and valuable. The only prognostic factor identified in relapsed patients seems to be time to relapse: patients relapsing later than 2 years from initial diagnosis have a better outcome [88]. Doxorubicin therapy is usually no longer feasible due to previously achieved cumulative doses. ChT regimens in relapse situations are not standardised and include alkylating agents (cyclophosphamide and high-dose ifosfamide) in combination with topoisomerase inhibitors (etoposide and topotecan), irinotecan with temozolomide [III, B] or gemcitabine and docetaxel, or high-dose ifosfamide or carboplatin with etoposide [89, 90]. The relative advantages of these different regimens are currently being tested in an international randomised study [European Organisation for Research and Treatment of Cancer (EORTC) trial 1403 European Clinical Trials Database (EudraCT) 2014-000259-99/ISRCTN36453794].

### High-grade spindle/pleomorphic sarcomas of bone

Pleomorphic sarcomas of bone comprise a diagnostically heterogeneous group of malignant tumours including undifferentiated pleomorphic sarcoma [8]. They arise in a similar age group to CS, but the skeletal distribution is more like OS. They typically present with pain and have a high incidence of fractures at presentation. They represent between 2% and 5% of primary bone malignancies. Males are more frequently affected than females. An association with pre-existing disease (Paget disease or bone infarct) or history of previous irradiation has been reported. It is not unusual for a spindle cell sarcoma to be found to be either a dedifferentiated CS or OS after examining further different sections of the resection. Therefore, the diagnosis should be established in a multidisciplinary setting and *IDH* mutation analysis should be considered when the radiological images suggest a CS.

Pleomorphic sarcomas typically present in older patients with a lytic lesion in bone. A metastatic lesion is often a differential diagnosis. Full staging and biopsy are required to reach a diagnosis. Pathological fractures are common and, as mentioned in the introduction, should not undergo internal fixation [91, 92]. Treatment strategies mimic those of OS, with ChT and complete *en bloc*

resection including any soft tissue component. Their sensitivity to ChT is poorly known, and studies on specific histologies as currently defined [especially after reappraisal of histologies previously known as malignant fibrous histiocytoma (MFH)], are highly required. RT may be considered in inoperable lesions. A global effort to collect these cases would be helpful to establish diagnostic and prognostic criteria as well as recommended treatments, for the whole group as well as for the different histologies.

### Chondrosarcoma

Most CSs arise as primary malignant tumours. The majority of CSs are low-grade, locally aggressive, non-metastasising tumours (atypical cartilaginous tumour/CS grade I), rather than high grade (grades II–III) [18, 93]. Grade I CSs can be labelled atypical cartilaginous tumours, as currently defined by the WHO 2013 classification, since they usually do not metastasise [18]. Grade I CSs may be treated with RT when located at critical sites such as the skull base. Most CSs arise centrally in the metaphyseal region of long bones, but they can also develop in flat bones such as pelvis, rib and scapula. High-grade CS frequently arises in the axial skeleton and long bones. CS can arise in pre-existing benign lesions such as enchondroma and osteochondroma [6]. In these circumstances, they are referred to as secondary central CSs and secondary peripheral CSs, respectively. The majority of CSs are of the conventional subtype, but rarer subtypes include mesenchymal and clear cell CS [33, 94]. In rare circumstances, conventional CSs can ‘dedifferentiate’ into a very high-grade tumour with a dismal prognosis: the so-called dedifferentiated CS [33, 94]. Most CSs are solitary, but they can occur as multiple lesions in syndromic patients with multiple osteochondromas and enchondromatosis [6].

Pain at the site of a cartilaginous lesion may be an indicator of malignancy. In the case of CS, a contrast-enhanced MRI can reveal high-grade areas. This provides a useful guide to the site of biopsy [95]. For large axial and pelvic CS, heterogeneity is common, and most lesions contain high-grade elements. The differentiation between benign enchondroma or osteochondroma and atypical cartilaginous tumour/CS grade I can be difficult, but can be aided by the use of dynamic contrast-enhanced MRI [96]. In the phalanges of the hands and feet, malignancy is extremely rare, but in the other long bones central cartilaginous lesions should be considered atypical cartilaginous tumour unless proven otherwise [94].

Inoperable, locally advanced and metastatic high-grade CSs have a poor prognosis [97]. Prognosis depends on histological grade. However, histological classification is subject to variability in interpretation, with grade II and III CSs often grouped together, even though there is a wide spectrum of outcome and heterogeneity of grade elements within tumours [74]. Also, grade I tumours (atypical cartilaginous tumours) are not necessarily curable in all cases, mainly due to problematic local recurrence or progression to high grade. Conversely, dedifferentiated CSs in particular are aggressive and frequently metastasise [33, 94].

Assessing the grade of CSs is difficult and discrepant diagnoses are common even among experts [93]. Atypical cartilaginous tumours are unlikely to metastasise, but may recur locally. Atypical cartilaginous tumours in the long bones of the limbs can be managed by curettage with or without local adjuvant (e.g. phenol, cement and cryotherapy), with a high chance of success.



Low-grade peripheral CSs (arising from osteochondromas) should be surgically excised, aiming to excise the tumour with a covering of normal tissue over it. Higher-grade CSs (grade II and III) and all CSs of the pelvis or axial skeleton should be surgically excised with wide margins [IV, B].

Evidence suggests that mesenchymal CS is more sensitive to ChT and therefore usually considered for adjuvant or neoadjuvant therapy [IV, C] [98, 99]. Most authors suggest a Ewing-type ChT regimen.

Dedifferentiated CS is often treated as a high-grade bone sarcoma, with systemic and local therapies that need to be adapted to patient's age [V, C] [100, 101]. There is a very high risk of local recurrence following excision of dedifferentiated CS, particularly in the presence of a pathological fracture. If wide margins cannot be reliably achieved with limb salvage, amputation should be considered.

The role of RT in CS is limited, but may be appropriate in highly selected cases or for palliation. Excellent outcomes have been reported for skull base CSs with high-dose RT, including proton or carbon ion beam RT, achieving 80%–90% local control rates [102].

With regard to ChT, drugs active in sarcomas such as doxorubicin and ifosfamide may prove active in CS, especially in high-grade lesions [97]. The activity of gemcitabine in combination with docetaxel has been reported [103].

### Giant cell tumour of bone

GCT of bone is a benign, locally aggressive and rarely metastatic tumour of the skeleton [9, 104]. GCT is classified in the intermediate category, as GCT can be aggressive and recurs locally in up to 50% of cases [9, 104]. Soft tissue extension is significantly associated with the risk of local recurrence. Up to 5% of GCTs metastasise to the lungs, and transformation to a high-grade malignancy though debated, may occur in 1%–3% of patients. GCTs of bone contain mutations in the *H3F3A* gene (predominantly at the G34 position) which can be detected using mutation analysis or immunohistochemistry using mutation-specific antibodies [104, 105].

Treatment options include *en bloc* excision [IV, A] and intralesional curettage with or without adjuvant in carefully selected cases. These have been assessed in a few prospective studies [106, 107]. Denosumab, a human monoclonal antibody to receptor activator of nuclear factor kappa B ligand (RANKL), known to be overexpressed in GCT, is standard treatment in unresectable or metastatic GCT [III, A] [107]. Its use in the neoadjuvant setting is debated and should be carried out exclusively in expert centres, and ideally within a clinical trial. There is increasing evidence that, if being used preoperatively and before curettage, surgery is best carried out after a few months of treatment, as otherwise extensive ossification may take place, making it difficult to define the extent of the lesion [V, C] [108]. It can also be used in unresectable disease and rare metastatic disease. In this setting, treatment interruption is usually followed by progression, so that treatment needs to be maintained [109]. Potential maxillary and skeletal side effects need to be monitored (osteonecrosis of the jaw, atypical fractures). The optimal schedule and duration of treatment with denosumab in surgically unsalvageable GCTs is still to be settled, and the possible long-term side effects are still largely unknown.

RT can provide a satisfactory local control in GCT (5-year control rate of 80%) [110]. However, the use of radiotherapy can be associated with a risk of GCT transformation into a high-grade sarcoma and can make surgical resection challenging if required. Therefore, the use of RT in GCTs should always be discussed in a multidisciplinary setting and be limited to cases in which surgery leads to unacceptable morbidity and denosumab is ineffective or contraindicated [IV, D].

### Chordoma

Chordoma is a rare bone tumour (incidence: 0.1 per 100 000 per year) arising from the persistent notochordal elements in the spine (sacrum 50% and bones from the mobile spine 20%) and in the skull base (30%). Extraskelatal cases are extremely rare.

Median age is 60 years, but skull base presentations can also affect a younger population, including children and adolescents. Conventional chordoma is a low-grade, locally-invasive malignancy. Immunohistochemistry nuclear positivity for Brachyury is the diagnostic hallmark and its assessment is strongly recommended [111]. Dedifferentiated chordomas account for less than 5% of all cases and behave more aggressively than the conventional counterpart. *T* expression can be lost in dedifferentiated chordoma. Approximately 30% of patients with chordoma will develop metastases, usually late in the natural history of the disease, and mostly after local recurrence.

Because of the extreme rarity and the challenging sites of origin, chordoma management should be carried out at referral centres and/or referral networks, with a multidisciplinary team including expert pathologists, radiologists, dedicated surgeons, radiation oncologists with access to hadron facilities, medical oncologists and a palliative care team.

Local staging should be carried out by MRI. Chordoma should be differentiated from benign notochordal cell tumours, benign lesions with peculiar radiological features believed to be chordoma precursors [112]. If radiological appearance is typical for benign notochordal cell tumours, biopsy is not recommended unless the lesion changes over time. For chordoma, preoperative core-needle biopsy is recommended and the biopsy track needs to be included in the surgical resection. For skull base chordoma, preoperative biopsy is not recommended if the tumour cannot be reached easily or safely, or if there is a high risk of tumour cell seeding [V, C] [113].

*En bloc* R0 resection is the recommended treatment, when feasible and sequelae are accepted by the patient [IV, B]. The expected 5-year recurrence-free survival is > 50%. For sacral chordoma, surgery should definitely be offered as a first choice in case of lesions arising from S4 (sacral spinal nerve 4) and below. It should always be discussed in the context of other alternatives for tumours originating above S3 (sacral spinal nerve 3), given the neurological sequelae associated to surgical resection. For skull base and upper cervical tract chordoma, R0 resection can rarely be done. R1 (microscopic positive margin) should be the goal of surgery in these cases [V, B]. Adjuvant RT should always be considered for skull base and cervical spine chordomas, and for sacral and mobile spine chordoma if R1-resected chordoma is observed in the final pathological examination.

If *en bloc* R0 resection is not feasible, the patient is inoperable or surgical sequelae are not accepted by the patient, definitive RT

alone (without debulking) is an alternative [V, C]. Particle therapy (high-dose protons or carbon ions) provide a better local control, survival and allow lower doses to be given to normal tissues and should, therefore, be considered the treatment of choice [IV, B] [114, 115]. Very conformal photon irradiation should only be proposed when similar dose uniformity within the target volume and dose to organs at risk can be achieved [V, B]. Due to the relative radiation resistance of chordomas, a high dose [up to at least 74 GyE in conventional fractionation (1.8–2 GyE) for photon and proton therapy] is required.

The use of neoadjuvant RT should be discussed with the single patient and prospective studies encouraged.

Local relapse has extremely poor survival rates and local control is rarely achievable. In the case of local relapse, possible salvage treatment can include surgery and/or RT and/or radiofrequency ablations and/or systemic treatment, balancing morbidity, quality of life and expected disease control [116].

For oligometastatic disease, surgery, radiofrequency ablations or stereotactic radiation can be considered in selected cases. ChT is inactive and is generally not recommended [V, D]. An exception can be high-grade dedifferentiated chordoma (anecdotal responses to ChT have been reported). There is uncontrolled evidence that imatinib and sorafenib can be beneficial in advanced chordoma in terms of progression-free survival and mainly non-dimensional tumour responses [117–119]. There are data on the activity of epidermal growth factor receptor and mammalian target of rapamycin (mTOR) inhibitors. Prospective studies are ongoing.

### Follow-up, long-term implications and survivorship

Follow-up is designed to detect either local recurrence or metastatic disease at a time when early treatment is still possible and might be effective. Follow-up of high-grade tumours should include both a physical examination of the tumour site and assessment of the function and possible complications of any reconstruction. Local imaging and chest X-ray/CT could be a proposed strategy. Strict rules cannot be provided in the absence of any formal prospective studies, and in the context of differing opinions in this panel of experts. A recommended follow-up policy may foresee intervals between checks after the completion of ChT, approximately every 3 months for the first 2 years; every 6 months for years 3–5; every 6–12 months for years 5–10, and thereafter every 0.5–2 years according to local practice and other factors. Chest CT, if used instead of chest X-rays, should be carried out with low-dose, radiation-sparing techniques, particularly in younger patients who will have a higher lifetime risk to experience second, radiation induced malignancies.

In the case of low-grade bone sarcoma, the frequency of follow-up visits may be lower (e.g. 6 months for 2 years and then annually). Late metastases as well as local recurrences and functional deficits may occur > 10 years after diagnosis and there is no universally accepted stopping point for tumour surveillance.

In ES, where osseous metastases are likely, isotope bone scanning can be used in addition to X-ray imaging but should be weighed against the additional radiation exposure, particularly in younger patients. More modern techniques (e.g. PET or whole-

body MRI) are increasingly being adopted into routine practice but require further evaluation in clinical trials. This is a general priority for all cancers.

There is a lack of consensus among experts about optimal follow-up policies, taking into consideration the specific risk and performance of systematic imaging follow-up regarding the median and long-term risk of second cancers. Some panellists propose 6-monthly follow-up, whereas others suggest 3-month intervals. Some propose interruption of systematic follow-up at 5 years, while others maintain it beyond 10 years. National guidelines may also be different across countries [120]. The lack of consensus and the very limited number of prospective trials point to the need to generate prospective clinical trials on this topic in the future.

It is important to evaluate the long-term toxic effects of ChT, surgery and RT for cured patients, given the incidence of late complications. Monitoring for late effects should be continued for > 10 years after treatment, depending on the ChT protocol and radiation used and in conjunction with late effects services when available. Long-term cardiac evaluation is of major importance since it has been shown that deterioration of cardiac function can still occur decades after anthracycline treatment [120–122].

Secondary cancers may arise in survivors of bone sarcomas, either related to, or independent of, irradiation. Secondary leukaemia, particularly acute myeloid leukaemia, may rarely be observed following ChT, as early as 2–5 years after treatment. Developments in genetic understanding of bone sarcoma point to the importance of obtaining a detailed family history and of genetic evaluation in high-risk families. Patients with cancer predisposition syndromes (e.g. Li–Fraumeni or Rothmund–Thomson syndromes) require special care and follow-up.

### Methodology

These Clinical Practice Guidelines have been produced by ESMO in partnership with EURACAN, the European Reference Network for rare adult solid cancers. These Clinical Practice Guidelines were developed in accordance with the ESMO standard operating procedures for Clinical Practice Guidelines development (<http://www.esmo.org/Guidelines/ESMO-Guidelines-Methodology>). They are conceived to provide the standard approach to diagnosis, treatment and survivorship on sarcomas, GISTs and bone sarcomas. Recommended interventions are intended to correspond to the ‘standard’ approaches, according to current consensus among the European multidisciplinary sarcoma community of experts. These are represented by the members of the ESMO Sarcoma Faculty and experts appointed by PaedCan and all institutions belonging to the Sarcoma domain of EURACAN.

Experimental interventions considered to be beneficial are labelled as ‘investigational’. Other non-standard approaches may be proposed to the single patient as ‘options’ for a shared patient physician decision in conditions of uncertainty, as long as some supporting evidence (though not conclusive) is available. Algorithms accompany the text, covering the main typical presentations of disease, and are meant to guide the user throughout the text. The relevant literature has been selected by the expert authors. A summary of recommendations is shown in Table 2. Levels of

**Table 2. Summary of recommendations****Diagnosis and pathology/molecular biology**

- Management of bone sarcomas should be carried out in a reference centre for bone sarcomas, with a primary biopsy under the supervision of a surgical team or dedicated interventional radiologist
- Pathological diagnosis should be made according to the 2013 WHO classification
- Medical history should focus on characteristic symptoms such as duration, intensity and timing of pain, persistent non-mechanical bone pain, swelling and functional impairment
- Diagnosis can be strongly oriented by patient age

**Staging and risk assessment**

- General staging should be carried out to assess the extent of distant disease, including bone scintigraphy, chest radiographs and CT, whole-body MRI and PET-CT or PET-MRI

**Treatment (locoregional and advanced disease)***Osteosarcoma*

- Adverse prognostic or predictive factors include detectable primary metastases, axial or proximal extremity tumour site, large tumour size, elevated serum AP or LDH and older age [III, B]
- Staging should include local imaging studies, specifically plain radiographs and MRI of the whole affected extremity [III, A]
- Curative treatment of high-grade OS consists of ChT and surgery [II, A]; multimodal ChT treatment is preferred
- Low-grade parosteal OSs are malignancies with a lower metastatic potential and should be treated by surgery alone [IV, B]
- Doxorubicin, cisplatin, HD-MTX and ifosfamide have antitumour activity in OS [I, A]. In patients aged > 40, preferred regimens often combine doxorubicin, cisplatin and ifosfamide without HD-MTX [III, B]
- In limited cases, RT including new techniques (e.g. proton and carbon ion beam RT) should be considered, particularly for unresectable primary tumours
- Primary metastatic OS patients are treated with a curative intent following the same principles of non-metastatic OSs
- High-grade craniofacial OS should be treated the same way as high-grade OS of other locations, although prospective evidence is lacking [IV, B]. RT, preferably within clinical studies, can be proposed when complete surgery is not feasible [IV, B]
- The treatment of recurrent OS is primarily surgical in the case of isolated lung metastases, although stereotactic RT, radiofrequency ablation or cryotherapy might be used as alternative options in patients unfit for surgery [IV, B]
- Radiofrequency ablation and stereotactic RT are potential alternative local treatment options for primary lung or bone metastases
- Second-line ChT for recurrent OS includes ifosfamide or cyclophosphamide, possibly in association with etoposide and/or carboplatin [III, B], and other active drugs including gemcitabine and docetaxel [IV, C], sorafenib [III, B] or regorafenib [II, B], as well as <sup>153</sup>Sm

*Ewing sarcoma*

- ES is a rare tumour and is usually treated within specific ChT regimens
- Treatment of patients with extraskelatal ES follows the same principles as for bone ES and incorporates ChT in all cases, as well as postoperative RT in most cases
- Complete surgical excision, where feasible, rather than RT alone, is regarded as the best modality of local tumour control
- RT alone should be applied if complete surgical excision is impossible
- Postoperative RT should be given in cases of inadequate surgical margins and discussed when histological response in the surgical specimen was poor [IV, B]
- Preferred ChT options include doxorubicin, cyclophosphamide, ifosfamide, vincristine, dactinomycin and etoposide, with most active protocols based on five- to six-drug combinations of these substances [I, A]
- Current trials employ 3–6 cycles of initial combination ChT after biopsy, followed by local therapy, and another 6–10 cycles of ChT, usually applied at 2- to 3-week intervals
- Dose-dense regimens (with interval compression) were associated with a positive outcome in paediatric and adolescent (<18 years) patients [II, B]
- Recent studies recommend the use of BuMeI for highly selected patients with poor response to induction ChT and/or tumour volume > 200 mL [I, B]
- For patients with metastases at diagnosis, ChT is similar to that for localised disease, but responses are less durable and patients have a worse prognosis
- ChT regimens in relapse situations are not standardised and include alkylating agents (cyclophosphamide and high-dose ifosfamide) in combination with topoisomerase inhibitors (etoposide and topotecan), irinotecan with temozolomide [III, B] or gemcitabine and docetaxel, or high-dose ifosfamide or carboplatin with etoposide

*High-grade spindle/pleomorphic sarcomas of bone*

- Treatment strategies mimic those of OS and include ChT and complete *en bloc* resection including any soft tissue component
- RT may be considered in inoperable lesions

*Chondrosarcoma*

- Mesenchymal CS is usually considered to be sensitive to adjuvant or neoadjuvant therapy [IV, C] and is treated using a Ewing-type ChT regimen
- Dedifferentiated CS is often treated as a high-grade bone sarcoma, with systemic and local therapies that need to be adapted to patient's age [IV, C]
- Skull base CSs can be treated with high-dose RT including proton or carbon ion beam RT
- Doxorubicin and ifosfamide may prove active in CS, especially in high-grade lesions, and gemcitabine in combination with docetaxel has also been reported to be effective

Continued

*Giant cell tumour of bone*

- Treatment options for GCTs include *en bloc* excision [IV, A] and intralesional curettage with or without adjuvant in carefully selected cases
- Denosumab is standard treatment in unresectable or metastatic GCT [III, A], although its use in the neoadjuvant setting is debated
- RT can provide local control in GCT but can be associated with transformation into a high-grade sarcoma, and should be limited to cases in which surgery leads to unacceptable morbidity and denosumab is ineffective or contraindicated [IV, D]

*Chordoma*

- Chordomas are very rare tumours, and management should be carried out at referral centres and/or referral networks with a multidisciplinary team
- *En bloc* R0 resection is standard treatment [IV, B], if feasible; otherwise, definitive RT alone should be considered as a valid alternative [V, C]
- For sacral chordoma, surgery should be offered if the chordoma arises from S4 and below or discussed in the context of other alternatives for tumours originating above S3. Surgery is preferred for tumours originating from S3, especially if the preservation of S2 roots is possible
- R1 surgery plus high-dose RT is the treatment of choice for skull base and upper cervical tract chordoma
- Indications for definitive RT include unresectable disease, inoperable patients and neurological impairment not accepted by the patient. RT should be considered in the case of R1 resections
- In the case of local relapse, recommended treatment includes surgery and/or RT and/or systemic treatment
- For oligometastatic disease, surgery/radiofrequency ablations/stereotactic radiation of metastases can be considered in selected cases
- Imatinib or sorafenib may be beneficial in advanced chordoma in terms of progression-free survival and mainly non-dimensional tumour responses

**Follow-up, long-term implications and survivorship**

- Follow-up of high-grade tumours should include both a physical examination of the tumour site and assessment of the function and possible complications of any reconstruction. Local imaging and chest X-ray/CT could be a proposed strategy
- A recommended follow-up policy varies among experts and may foresee intervals between checks after the completion of ChT, approximately every 3 months for the first 2 years; every 6 months for years 3–5; every 6–12 months for years 5–10, and thereafter every 0.5–2 years
- Chest CT, if used instead of chest X-rays, should be carried out with low-dose, radiation-sparing techniques
- For low-grade bone sarcoma, the frequency of follow-up visits may be lower (e.g. 6 months for 2 years and then annually)
- In ES, where osseous metastases are likely, isotope bone scanning can be used in addition to X-ray imaging but should be weighed against the additional radiation exposure
- More modern techniques (e.g. PET or whole-body MRI) are increasingly being adopted into routine practice but require further evaluation in clinical trials
- Long-term toxic effects of ChT, surgery and RT should be evaluated, and monitoring for late effects should be continued for > 10 years after treatment, depending on the ChT protocol and radiation used
- Long-term cardiac evaluation is important, as it has been shown that deterioration of cardiac function can still occur decades after anthracycline treatment
- Secondary cancers may arise in survivors of bone sarcomas, either related to, or independent of, irradiation. Secondary leukaemia, particularly acute myeloid leukaemia, may rarely be observed following ChT, as early as 2–5 years after treatment

AP, alkaline phosphatase; BuMel, busulfan and melphalan; ChT, chemotherapy; CS, chondrosarcoma; CT, computed tomography; ES, Ewing sarcoma; GCT, giant cell tumour; HD-MTX, high-dose methotrexate; LDH, lactate dehydrogenase; MRI, magnetic resonance imaging; OS, osteosarcoma; PET, positron emission tomography; R0, no tumour at the margin; R1, microscopic tumour at the margin; RT, radiotherapy; S2–S4, sacral spinal nerve 2–4; WHO, World Health Organization.

evidence and grades of recommendation have been applied using the system shown in Table 3. Statements without grading were considered justified standard clinical practice by the experts.

**Disclosure**

PGC has reported advisory roles for Deciphera Pharmaceuticals, Eisai, Eli Lilly, Nektar Therapeutics, speaker's honoraria from Eisai, Eli Lilly, Pfizer, PharmaMar, and conducted studies sponsored by Amgen Dompé, AROG Bayer, Blueprint Medicines, Eli Lilly, Daiichi Sankyo Pharma, Epizyme, GlaxoSmithKline, Novartis, Pfizer, PharmaMar; SBI has reported advisory/consultant roles for Lilly, Bayer, Pfizer, Novartis, Isolfol and Clinigen and conducted studies sponsored by Janssen-Cilag, Eisai and Loxo Oncology; SBa has reported research support from Novartis, Incyte, Blueprint Medicines, has received honoraria or consultation fees from Novartis, Lilly, Pfizer, PharmaMar and Bayer; SBI has reported advisory/consultant roles for Lilly, Bayer,

Pfizer, Novartis, Isolfol and Clinigen and conducted studies sponsored by Janssen-Cilag, Eisai and Loxo Oncology; SBo has reported honoraria and travel grants from Nanobiotix and Lilly and received travel grants from PharmaMar; IB has reported research funds from MSD, Bristol-Myers Squibb, Novartis, Roche, Regeneron, Amgen, Astra-Zeneca, Boehringer Ingelheim and Genesis and advisory boards, honorarium and travel expenses from MSD, Bristol-Myers Squibb, Novartis, Roche, Amgen, Astra-Zeneca, Boehringer Ingelheim, LEO Pharma, Galenica, Genesis and Sanofi; JVMGB has received a research grant from Servier and honoraria from Nanobiotix for reviewing cases for their trial; TB has reported honoraria from Roche and PharmaMar and advisory board and honoraria from Amgen, Bayer, Novartis, Eisai and Eli Lilly; JMB has reported consulting advisory role for PharmaMar, Lilly, Bayer, Novartis and being a member of the speaker's bureau for PharmaMar and received travel grants from PharmaMar and Lilly; EDA has received honoraria from PharmaMar, Roche, Lilly and Pfizer and travel grants from Roche; APDT is a member of the speakers' bureau for Lilly,

**Table 3. Levels of evidence and grades of recommendation (adapted from the Infectious Diseases Society of America-United States Public Health Service Grading System<sup>a</sup>)****Levels of evidence**

I	Evidence from at least one large randomised, controlled trial of good methodological quality (low potential for bias) or meta-analyses of well-conducted randomised trials without heterogeneity
II	Small randomised trials or large randomised trials with a suspicion of bias (lower methodological quality) or meta-analyses of such trials or of trials with demonstrated heterogeneity
III	Prospective cohort studies
IV	Retrospective cohort studies or case-control studies
V	Studies without control group, case reports, experts opinions

**Grades of recommendation**

A	Strong evidence for efficacy with a substantial clinical benefit, strongly recommended
B	Strong or moderate evidence for efficacy but with a limited clinical benefit, generally recommended
C	Insufficient evidence for efficacy or benefit does not outweigh the risk or the disadvantages (adverse events, costs, . . .), optional
D	Moderate evidence against efficacy or for adverse outcome, generally not recommended
E	Strong evidence against efficacy or for adverse outcome, never recommended

<sup>a</sup>By permission of the Infectious Diseases Society of America [123].

Pfizer and Merck Sharp & Dohme; XGDM has reported advisory role for Lilly, PharmaMar and Novartis; PD has reported conducted research sponsored by Eli Lilly; ME has participated in advisory boards for Bayer, Sobi, Lilly, Eisai and Novartis; AMF has conducted studies sponsored by Amgen Dompé, AROG Bayer, Blueprint Medicines, Eli Lilly, Daiichi Sankyo Pharma, Epizyme, GlaxoSmithKline, Novartis, Pfizer, PharmaMar; SG has received research grants and honoraria from Novartis, Pfizer and Bayer; HG has received research grants from Novartis, Daiichi Sankyo Pharma and Pfizer; AG has reported compensation for advisory boards from Novartis, Pfizer, Bayer, Lilly, PharmaMar and Nanobiotix, honoraria from Novartis, Lilly, PharmaMar and Nanobiotix, and research funds from PharmaMar and travel grants from PharmaMar and Nanobiotix; BH has received research grants from EuroSarc and has conducted research with EIT Health in collaboration with GE Healthcare and Philips and has received reagents from Takeda and Astellas to conduct clinical trials without direct funding; PH has reported conducting research sponsored by Novartis, Blueprint Medicines, Nanobiotix and Lilly and has received honoraria and travel grants from PharmaMar, Eisai and Lilly; HJ has reported co-appointment with Orion Pharma and holds stock in Sartar Therapeutics, Faron Pharmaceuticals and Orion Pharma; RLJ is a consultant for Adaptimmune, Blueprint Medicines, Clinigen, Eisai, Epizyme, Daichii, Deciphera, Immunodesign, Lilly, Merck and PharmaMar; IJ has received honoraria from Lilly for lectures; PJ has reported being a consultant for Stryker for the design of a new tumour prosthesis; BK has reported honoraria from Bayer, Lilly, Novartis and PharmaMar, advisory role for Bayer and Lilly and travel grants from PharmaMar; KK has received travel grants from Novartis and Pfizer; ALC has received honoraria from Pfizer, Novartis, Lilly, Amgen, Bayer and PharmaMar; IL has received honoraria from Bristol-Myers Squibb, Merck Sharp & Dohme, Roche, Novartis and Pfizer for scientific presentations or research; MAP has served on advisory boards for Bayer and Pfizer, and has received research grants from Novartis; PRe has served on advisory boards for Novartis, Pfizer, PharmaMar,

Ariad, Merck, Deciphera, Roche, Clinigen and Lilly and has received honoraria from Novartis, Pfizer, Bayer, PharmaMar and Lilly; PRu has received honoraria for lectures from Novartis, Pfizer, Bristol-Myers Squibb, Merck Sharp & Dohme, Roche and has served as a member of advisory board for Novartis, Amgen, Merck Sharp & Dohme, Bristol-Myers Squibb, Blueprint Medicines; PS has received honoraria from Daiichi Sankyo Pharma, Eisai, Eli Lilly, Medspace, Novartis, Swedish Orphan Biovitrium, has reported consulting or advising roles for Sixth Element Capital, Adaptimmune, Amcure, AstraZeneca, Bayer, Blueprint Medicines, Bristol-Myers Squibb, Boehringer Ingelheim, Cristal Therapeutics, Daiichi Sankyo Pharma, Eisai, Eli Lilly, Epizyme, Genzyme, Ipsen, Loxo Oncology, Medspace, Nektar, Novartis, Philogen, Piqu Therapeutics, Plexxikon, is a member of speaker's bureau of Bayer, Eisai, Eli Lilly, GlaxoSmithKline, Novartis, PharmaMar, Swedish Orphan Biovitrium, has received research grants from Bayer, Blueprint Medicines, CoBioRes, Exelixis, Bristol-Myers Squibb, Novartis, Plexxikon, and has received travel grants from Sixth Element Capital, Adaptimmune, Amcure, AstraZeneca, Bayer, Blueprint Medicines, Bristol-Myers Squibb, Boehringer Ingelheim, Cristal Therapeutics, Daichii Sankyo Pharma, Eisai, Eli Lilly, Epizyme, Genzyme, GlaxoSmithKline, Ipsen, Loxo Oncology, Medpace, Nektar, Novartis, PharmaMar, Philogen, Piqu Therapeutics, Plexxikon, Swedish Orphan Biovitrium; SSt has received honoraria from Eli Lilly and PharmaMar, research grants from Amgen Dompé, Advenchen, Bayer, Eli Lilly, Daiichi Sankyo Pharma, Epizyme Inc., Novartis, Pfizer and PharmaMar; travel grants from PharmaMar and has reported advisory/consultant roles for Bayer, Eli Lilly, ImmuneDesign, Maxivax and PharmaMar; WVdG has received research grants from Novartis; EW has reported travel/research grants and/or honoraria from Novartis Oncology, Milestone, Menarini, PharmaMar, Roche, Nanobiotix and Bayer; JYB has declared research grants and honoraria from Novartis, GlaxoSmithKline, Pfizer and Bayer; NA, RB, BB, LB, AB, CD, FF, AFed, VF, AFer, NG, TG, RLH, SHN, RI, SK, LK, DAK, RL, OM, MM, BM, RP, PP, SP-N, ALP, MHR, AAS, SSI,

SSt, KSH, MU, JW and FVC have declared no conflicts of interest. SF, AH and OZ have not reported any potential conflicts of interest.

## References

1. Stiller CA, Trama A, Serraino D. Descriptive epidemiology of sarcomas in Europe: report from the RARECARE project. *Eur J Cancer* 2013; 49: 684–695.
2. Whelan J, McTiernan A, Cooper N et al. Incidence and survival of malignant bone sarcomas in England 1979–2007. *Int J Cancer* 2012; 131: E508–E517.
3. Valery PC, Laversanne M, Bray F. Bone cancer incidence by morphological subtype: a global assessment. *Cancer Causes Control* 2015; 26: 1127–1139.
4. Van den Berg H, Kroon HM, Slaar A, Hogendoorn P. Incidence of biopsy-proven bone tumors in children: a report based on the Dutch pathology registration “PALGA”. *J Pediatr Orthop* 2008; 28: 29–35.
5. Fuchs B, Pritchard DJ. Etiology of osteosarcoma. *Clin Orthop Relat Res* 2002; 397: 40–52.
6. Bovée JV, Cleton-Jansen AM, Taminiau AH, Hogendoorn PC. Emerging pathways in the development of chondrosarcoma of bone and implications for targeted treatment. *Lancet Oncol* 2005; 6: 599–607.
7. Grünwald TG, Bernard V, Gilardi-Hebenstreit P et al. Chimeric EWSR1–FLI1 regulates the Ewing sarcoma susceptibility gene EGR2 via a GGAA microsatellite. *Nat Genet* 2015; 47: 1073–1078.
8. Pakos EE, Grimer RJ, Peake D et al. The ‘other’ bone sarcomas: prognostic factors and outcomes of spindle cell sarcomas of bone. *J Bone Joint Surg Br* 2011; 93: 1271–1278.
9. Liede A, Bach BA, Stryker S et al. Regional variation and challenges in estimating the incidence of giant cell tumor of bone. *J Bone Joint Surg Am* 2014; 96: 1999–2007.
10. Hauben EI, Hogendoorn PCW. Epidemiology of primary bone tumors and economical aspects of bone metastases. In D Heymann (ed.), *Bone Cancer. Progression and Therapeutic Approaches*, 1st edition. London: Academic Press 2009; 3–8.
11. Malhas AM, Grimer RJ, Abudu A et al. The final diagnosis in patients with a suspected primary malignancy of bone. *J Bone Joint Surg Br* 2011; 93: 980–983.
12. Grimer RJ, Briggs TW. Earlier diagnosis of bone and soft-tissue tumours. *J Bone Joint Surg Br* 2010; 92: 1489–1492.
13. Meyer JS, Nadel HR, Marina N et al. Imaging guidelines for children with Ewing sarcoma and osteosarcoma: a report from the Children’s Oncology Group Bone Tumor Committee. *Pediatr Blood Cancer* 2008; 51: 163–170.
14. Andreou D, Bielack SS, Carrle D et al. The influence of tumor- and treatment-related factors on the development of local recurrence in osteosarcoma after adequate surgery. An analysis of 1355 patients treated on neoadjuvant Cooperative Osteosarcoma Study Group protocols. *Ann Oncol* 2011; 22: 1228–1235.
15. Blay JY, Soibinet P, Penel N et al. Improved survival using specialized multidisciplinary board in sarcoma patients. *Ann Oncol* 2017; 28: 2852–2859.
16. van den Berg H, Slaar A, Kroon HM et al. Results of diagnostic review in pediatric bone tumors and tumorlike lesions. *J Pediatr Orthop* 2008; 28: 561–564.
17. Mankin HJ, Lange TA, Spanier SS. The hazards of biopsy in patients with malignant primary bone and soft-tissue tumors. *J Bone Joint Surg Am* 1982; 64: 1121–1127.
18. Fletcher CDM, Bridge JA, Hogendoorn PCW, Mertens F. *Pathology and genetics of tumours of soft tissue and bone*. World Health Organization. Lyon: IARC Press 2013.
19. Abdul-Karim FW, Bauer TW, Kilpatrick SE et al. Recommendations for the reporting of bone tumors. *Association of Directors of Anatomic and Surgical Pathology. Hum Pathol* 2004; 35: 1173–1178.
20. Enneking WF, Spanier SS, Goodman MA. A system for the surgical staging of musculoskeletal sarcoma. *Clin Orthop Relat Res* 1980; 106–120.
21. Heck RK Jr, Peabody TD, Simon MA. Staging of primary malignancies of bone. *CA Cancer J Clin* 2006; 56: 366–375.
22. Brierley JD, Gospodarowicz MK, Wittekind C (eds). *TNM Classification of Malignant Tumours*, 8th edn. Oxford: John Wiley & Sons, Inc. 2016.
23. Picci P, Vanel D, Briccoli A et al. Computed tomography of pulmonary metastases from osteosarcoma: the less poor technique. A study of 51 patients with histological correlation. *Ann Oncol* 2001; 12: 1601–1604.
24. Buchbender C, Heusner TA, Lauenstein TC et al. Oncologic PET/MRI, part 2: bone tumors, soft-tissue tumors, melanoma, and lymphoma. *J Nucl Med* 2012; 53: 1244–1252.
25. Bramer JA, van Linge JH, Grimer RJ, Scholten RJ. Prognostic factors in localized extremity osteosarcoma: a systematic review. *Eur J Surg Oncol* 2009; 35: 1030–1036.
26. Bielack SS, Kempf-Bielack B, Delling G et al. Prognostic factors in high-grade osteosarcoma of the extremities or trunk: an analysis of 1,702 patients treated on neoadjuvant cooperative osteosarcoma study group protocols. *J Clin Oncol* 2002; 20: 776–790.
27. Picci P, Sangiorgi L, Rougraff BT et al. Relationship of chemotherapy-induced necrosis and surgical margins to local recurrence in osteosarcoma. *J Clin Oncol* 1994; 12: 2699–2705.
28. Grimer RJ, Bielack S, Flege S et al. Periosteal osteosarcoma—a European review of outcome. *Eur J Cancer* 2005; 41: 2806–2811.
29. Cesari M, Alberghini M, Vanel D et al. Periosteal osteosarcoma: a single-institution experience. *Cancer* 2011; 117: 1731–1735.
30. Laitinen M, Parry M, Albergo JI et al. The prognostic and therapeutic factors which influence the oncological outcome of parosteal osteosarcoma. *Bone Joint J* 2015; 97-B: 1698–1703.
31. Bramer JA, Abudu AA, Grimer RJ et al. Do pathological fractures influence survival and local recurrence rate in bony sarcomas? *Eur J Cancer* 2007; 43: 1944–1951.
32. Ferrari S, Smeland S, Mercuri M et al. Neoadjuvant chemotherapy with high-dose ifosfamide, high-dose methotrexate, cisplatin, and doxorubicin for patients with localized osteosarcoma of the extremity: a joint study by the Italian and Scandinavian Sarcoma Groups. *J Clin Oncol* 2005; 23: 8845–8852.
33. Whelan JS, Davis LE. Osteosarcoma, chondrosarcoma, and chordoma. *J Clin Oncol* 2018; 36: 188–193.
34. Bielack SS, Smeland S, Whelan JS et al. Methotrexate, doxorubicin, and cisplatin (MAP) plus maintenance pegylated interferon alfa-2b versus MAP alone in patients with resectable high-grade osteosarcoma and good histologic response to preoperative map: first results of the EURAMOS-1 good response randomized controlled trial. *J Clin Oncol* 2015; 33: 2279–2287.
35. Whelan JS, Bielack SS, Marina N et al. EURAMOS-1, an international randomised study for osteosarcoma: results from pre-randomisation treatment. *Ann Oncol* 2015; 26: 407–414.
36. Marina NM, Smeland S, Bielack SS et al. Comparison of MAPIE versus MAP in patients with a poor response to preoperative chemotherapy for newly diagnosed high-grade osteosarcoma (EURAMOS-1): an open-label, international, randomised controlled trial. *Lancet Oncol* 2016; 17: 1396–1408.
37. Lewis IJ, Nooij MA, Whelan J et al. Improvement in histologic response but not survival in osteosarcoma patients treated with intensified chemotherapy: a randomized phase III trial of the European Osteosarcoma Intergroup. *J Natl Cancer Inst* 2007; 99: 112–128.
38. Carrle D, Bielack SS. Current strategies of chemotherapy in osteosarcoma. *Int Orthop* 2006; 30: 445–451.
39. Bielack SS, Machatschek JN, Flege S, Jürgens H. Delaying surgery with chemotherapy for osteosarcoma of the extremities. *Expert Opin Pharmacother* 2004; 5: 1243–1256.
40. Goorin AM, Schwartztruber DJ, Devidas M et al. Presurgical chemotherapy compared with immediate surgery and adjuvant chemotherapy for nonmetastatic osteosarcoma: Pediatric Oncology Group Study POG-8651. *J Clin Oncol* 2003; 21: 1574–1580.

41. Meyers PA, Schwartz CL, Krailo MD et al. Osteosarcoma: the addition of muramyl tripeptide to chemotherapy improves overall survival—a report from the Children’s Oncology Group. *J Clin Oncol* 2008; 26: 633–638.
42. Hunsberger S, Freidlin B, Smith MA. Complexities in interpretation of osteosarcoma clinical trial results. *J Clin Oncol* 2008; 26: 3103–3104; author reply 3104–3105.
43. van der Woude HJ, Bloem JL, Hogendoorn PC. Preoperative evaluation and monitoring chemotherapy in patients with high-grade osteogenic and Ewing’s sarcoma: review of current imaging modalities. *Skeletal Radiol* 1998; 27: 57–71.
44. van der Woude HJ, Bloem JL, Verstraete KL et al. Osteosarcoma and Ewing’s sarcoma after neoadjuvant chemotherapy: value of dynamic MR imaging in detecting viable tumor before surgery. *AJR Am J Roentgenol* 1995; 165: 593–598.
45. Piperno-Neumann S, Le Deley MC, Rédini F et al. Zoledronate in combination with chemotherapy and surgery to treat osteosarcoma (OS2006): a randomised, multicentre, open-label, phase 3 trial. *Lancet Oncol* 2016; 17: 1070–1080.
46. Ferrari S, Bielack SS, Smeland S et al. EURO-B.O.S.S.: a European study on chemotherapy in bone-sarcoma patients aged over 40: outcome in primary high-grade osteosarcoma. *Tumori* 2018; 104: 30–36.
47. Leroy R, Benahmed N, Hulstaert F et al. Proton therapy in children: a systematic review of clinical effectiveness in 15 pediatric cancers. *Int J Radiat Oncol Biol Phys* 2016; 95: 267–278.
48. Kager L, Zoubek A, Potschger U et al. Primary metastatic osteosarcoma: presentation and outcome of patients treated on neoadjuvant Cooperative Osteosarcoma Study Group protocols. *J Clin Oncol* 2003; 21: 2011–2018.
49. Ferrari S, Briccoli A, Mercuri M et al. Postrelapse survival in osteosarcoma of the extremities: prognostic factors for long-term survival. *J Clin Oncol* 2003; 21: 710–715.
50. Frezza AM, Beale T, Bomanji J et al. Is [F-18]-fluorodeoxy-D-glucose positron emission tomography of value in the management of patients with craniofacial bone sarcomas undergoing neo-adjuvant treatment? *BMC Cancer* 2014; 14: 23.
51. Kempf-Bielack B, Bielack SS, Jurgens H et al. Osteosarcoma relapse after combined modality therapy: an analysis of unselected patients in the Cooperative Osteosarcoma Study Group (COSS). *J Clin Oncol* 2005; 23: 559–568.
52. de Baere T, Tselikas L, Gravel G et al. Interventional radiology: role in the treatment of sarcomas. *Eur J Cancer* 2018; 94: 148–155.
53. Saumet L, Deschamps F, Marec-Berard P et al. Radiofrequency ablation of metastases from osteosarcoma in patients under 25 years: the SCFE experience. *Pediatr Hematol Oncol* 2015; 32: 41–49.
54. Yu W, Liu Z, Tang L et al. Efficacy and safety of stereotactic radio surgery for pulmonary metastases from osteosarcoma: experience in 73 patients. *Sci Rep* 2017; 7: 17480.
55. Palmerini E, Jones RL, Marchesi E et al. Gemcitabine and docetaxel in relapsed and unresectable high-grade osteosarcoma and spindle cell sarcoma of bone. *BMC Cancer* 2016; 16: 280.
56. Grignani G, Palmerini E, Ferraresi V et al. Sorafenib and everolimus for patients with unresectable high-grade osteosarcoma progressing after standard treatment: a non-randomised phase 2 clinical trial. *Lancet Oncol* 2015; 16: 98–107.
57. Duffaud F. Regorafenib shows promise in osteosarcoma, no benefit in liposarcoma - REGOBONE study (Abstract 11504). ASCO 2018 (annual meeting of the American Society of Clinical Oncology), Sarcoma Oral Abstract Session: abstr 11504.
58. Fagioli F, Aglietta M, Tienghi A et al. High-dose chemotherapy in the treatment of relapsed osteosarcoma: an Italian sarcoma group study. *J Clin Oncol* 2002; 20: 2150–2156.
59. Berger M, Grignani G, Ferrari S et al. Phase 2 trial of two courses of cyclophosphamide and etoposide for relapsed high-risk osteosarcoma patients. *Cancer* 2009; 115: 2980–2987.
60. Berger M, Grignani G, Giostra A et al. 153Samarium-EDTMP administration followed by hematopoietic stem cell support for bone metastases in osteosarcoma patients. *Ann Oncol* 2012; 23: 1899–1905.
61. Aurias A, Rimbaut C, Buffe D et al. Translocation involving chromosome 22 in Ewing’s sarcoma. A cytogenetic study of four fresh tumors. *Cancer Genet Cytogenet* 1984; 12: 21–25.
62. Grünewald TGP, Cidre-Aranaz F, Surdez D et al. Ewing sarcoma. *Nat Rev Dis Primers* 2018; 4: 5 (review).
63. Zoubek A, Pfeleiderer C, Salzer-Kuntschik M et al. Variability of EWS chimaeric transcripts in Ewing tumours: a comparison of clinical and molecular data. *Br J Cancer* 1994; 70: 908–913.
64. Sorensen PH, Lessnick SL, Lopez-Terrada D et al. A second Ewing’s sarcoma translocation, t(21;22), fuses the EWS gene to another ETS-family transcription factor, ERG. *Nat Genet* 1994; 6: 146–151.
65. Antonescu CR, Owosho AA, Zhang L et al. Sarcomas with CIC-rearrangements are a distinct pathologic entity with aggressive outcome: a clinicopathologic and molecular study of 115 cases. *Am J Surg Pathol* 2017; 41: 941–949.
66. Yamada Y, Kuda M, Kohashi K et al. Histological and immunohistochemical characteristics of undifferentiated small round cell sarcomas associated with CIC-DUX4 and BCOR-CCNB3 fusion genes. *Virchows Arch* 2017; 470: 373–380.
67. Machado I, Noguera R, Pellin A et al. Molecular diagnosis of Ewing sarcoma family of tumors: a comparative analysis of 560 cases with FISH and RT-PCR. *Diagn Mol Pathol* 2009; 18: 189–199.
68. Newman EN, Jones RL, Hawkins DS. An evaluation of [F-18]-fluorodeoxy-D-glucose positron emission tomography, bone scan, and bone marrow aspiration/biopsy as staging investigations in Ewing sarcoma. *Pediatr Blood Cancer* 2013; 60: 1113–1117.
69. Cangir A, Vietti TJ, Gehan EA et al. Ewing’s sarcoma metastatic at diagnosis. Results and comparisons of two intergroup Ewing’s sarcoma studies. *Cancer* 1990; 66: 887–893.
70. Bernstein ML, Devidas M, Lafreniere D et al. Intensive therapy with growth factor support for patients with Ewing tumor metastatic at diagnosis: Pediatric Oncology Group/Children’s Cancer Group Phase II Study 9457—a report from the Children’s Oncology Group. *J Clin Oncol* 2006; 24: 152–159.
71. Bacci G, Ferrari S, Bertoni F et al. Prognostic factors in nonmetastatic Ewing’s sarcoma of bone treated with adjuvant chemotherapy: analysis of 359 patients at the Istituto Ortopedico Rizzoli. *J Clin Oncol* 2000; 18: 4–11.
72. Bacci G, Forni C, Longhi A et al. Long-term outcome for patients with non-metastatic Ewing’s sarcoma treated with adjuvant and neoadjuvant chemotherapies. 402 patients treated at Rizzoli between 1972 and 1992. *Eur J Cancer* 2004; 40: 73–83.
73. Cotterill SJ, Ahrens S, Paulussen M et al. Prognostic factors in Ewing’s tumor of bone: analysis of 975 patients from the European Intergroup Cooperative Ewing’s Sarcoma Study Group. *J Clin Oncol* 2000; 18: 3108–3114.
74. Leavey PJ, Collier AB. Ewing sarcoma: prognostic criteria, outcomes and future treatment. *Expert Rev Anticancer Ther* 2008; 8: 617–624.
75. Le Deley MC, Delattre O, Schaefer KL et al. Impact of EWS-ETS fusion type on disease progression in Ewing’s sarcoma/peripheral primitive neuroectodermal tumor: prospective results from the cooperative Euro-E.W.I.N.G. 99 trial. *J Clin Oncol* 2010; 28: 1982–1988.
76. van Doorninck JA, Ji L, Schaub B et al. Current treatment protocols have eliminated the prognostic advantage of type 1 fusions in Ewing sarcoma: a report from the Children’s Oncology Group. *J Clin Oncol* 2010; 28: 1989–1994.
77. Nesbit ME Jr, Gehan EA, Burgert EO Jr et al. Multimodal therapy for the management of primary, nonmetastatic Ewing’s sarcoma of bone: a long-term follow-up of the First Intergroup study. *J Clin Oncol* 1990; 8: 1664–1674.
78. Schuck A, Ahrens S, Paulussen M et al. Local therapy in localized Ewing tumors: results of 1058 patients treated in the CESS 81, CESS 86, and EICESS 92 trials. *Int J Radiat Oncol Biol Phys* 2003; 55: 168–177.

79. Grier HE, Krailo MD, Tarbell NJ et al. Addition of ifosfamide and etoposide to standard chemotherapy for Ewing's sarcoma and primitive neuroectodermal tumor of bone. *N Engl J Med* 2003; 348: 694–701.
80. Paulussen M, Craft AW, Lewis I et al. Results of the EICESS-92 study: two randomized trials of Ewing's sarcoma treatment–cyclophosphamide compared with ifosfamide in standard-risk patients and assessment of benefit of etoposide added to standard treatment in high-risk patients. *J Clin Oncol* 2008; 26: 4385–4393.
81. Gaspar N, Hawkins DS, Dirksen U et al. Ewing sarcoma: current management and future approaches through collaboration. *J Clin Oncol* 2015; 33: 3036–3046.
82. Womer RB, West DC, Krailo MD et al. Randomized controlled trial of interval-compressed chemotherapy for the treatment of localized Ewing sarcoma: a report from the Children's Oncology Group. *J Clin Oncol* 2012; 30: 4148–4154.
83. Ferrari S, Sundby Hall K, Luksch R et al. Nonmetastatic Ewing family tumors: high-dose chemotherapy with stem cell rescue in poor responder patients. Results of the Italian Sarcoma Group/Scandinavian Sarcoma Group III protocol. *Ann Oncol* 2011; 22: 1221–1227.
84. Whelan J, Le Deley MC, Dirksen U et al. Efficacy of busulfan-melphalan high dose chemotherapy consolidation (BuMel) in localized high-risk Ewing sarcoma (ES): results of EURO-EWING 99-R2 randomized trial (EE99R2Loc). *J Clin Oncol* 2016; 34 (15\_Suppl): 11000.
85. Shapeero LG, Vanel D. Imaging evaluation of the response of high-grade osteosarcoma and Ewing sarcoma to chemotherapy with emphasis on dynamic contrast-enhanced magnetic resonance imaging. *Semin Musculoskelet Radiol* 2000; 4: 137–146.
86. Bölling T, Schuck A, Paulussen M et al. Whole lung irradiation in patients with exclusively pulmonary metastases of Ewing tumors. Toxicity analysis and treatment results of the EICESS-92 trial. *Strahlenther Onkol* 2008; 184: 193–197.
87. Haeusler J, Ranft A, Boelling T et al. The value of local treatment in patients with primary, disseminated, multifocal Ewing sarcoma (PDMES). *Cancer* 2010; 116: 443–450.
88. Stahl M, Ranft A, Paulussen M et al. Risk of recurrence and survival after relapse in patients with Ewing sarcoma. *Pediatr Blood Cancer* 2011; 57: 549–553.
89. Ferrari S, del Prever AB, Palmerini E et al. Response to high-dose ifosfamide in patients with advanced/recurrent Ewing sarcoma. *Pediatr Blood Cancer* 2009; 52: 581–584.
90. Hunold A, Weddeling N, Paulussen M et al. Topotecan and cyclophosphamide in patients with refractory or relapsed Ewing tumors. *Pediatr Blood Cancer* 2006; 47: 795–800.
91. Bramwell VH, Steward WP, Nooij M et al. Neoadjuvant chemotherapy with doxorubicin and cisplatin in malignant fibrous histiocytoma of bone: A European Osteosarcoma Intergroup study. *J Clin Oncol* 1999; 17: 3260–3269.
92. Nooij MA, Whelan J, Bramwell VH et al. Doxorubicin and cisplatin chemotherapy in high-grade spindle cell sarcomas of the bone, other than osteosarcoma or malignant fibrous histiocytoma: A European Osteosarcoma Intergroup study. *Eur J Cancer* 2005; 41: 225–230.
93. Eefting D, Schrage YM, Geirnaerd MJ et al. Assessment of interobserver variability and histologic parameters to improve reliability in classification and grading of central cartilaginous tumors. *Am J Surg Pathol* 2009; 33: 50–57.
94. Gelderblom H, Hogendoorn PC, Dijkstra SD et al. The clinical approach towards chondrosarcoma. *Oncologist* 2008; 13: 320–329.
95. Geirnaerd MJ, Hogendoorn PC, Bloem JL et al. Cartilaginous tumors: fast contrast-enhanced MR imaging. *Radiology* 2000; 214: 539–546.
96. De Coninck T, Jans L, Sys G et al. Dynamic contrast-enhanced MR imaging for differentiation between enchondroma and chondrosarcoma. *Eur Radiol* 2013; 23: 3140–3152.
97. Italiano A, Mir O, Cioffi A et al. Advanced chondrosarcomas: role of chemotherapy and survival. *Ann Oncol* 2013; 24: 2916–2922.
98. Dantonello TM, Int-Veen C, Leuschner I et al. Mesenchymal chondrosarcoma of soft tissues and bone in children, adolescents, and young adults: experiences of the CWS and COSS study groups. *Cancer* 2008; 112: 2424–2431.
99. Frezza AM, Cesari M, Baumhoer D et al. Mesenchymal chondrosarcoma: prognostic factors and outcome in 113 patients. A European Musculoskeletal Oncology Society study. *Eur J Cancer* 2015; 51: 374–381.
100. Dickey ID, Rose PS, Fuchs B et al. Dedifferentiated chondrosarcoma: the role of chemotherapy with updated outcomes. *J Bone Joint Surg Am* 2004; 86-A: 2412–2418.
101. Grimer RJ, Gosheger G, Taminiau A et al. Dedifferentiated chondrosarcoma: prognostic factors and outcome from a European group. *Eur J Cancer* 2007; 43: 2060–2065.
102. Noel G, Feuvret L, Ferrand R et al. Radiotherapeutic factors in the management of cervical-basal chordomas and chondrosarcomas. *Neurosurgery* 2004; 55: 1252–1260; discussion 1260–1262.
103. Fox E, Patel S, Wathen JK et al. Phase II study of sequential gemcitabine followed by docetaxel for recurrent Ewing sarcoma, osteosarcoma, or unresectable or locally recurrent chondrosarcoma: results of Sarcoma Alliance for Research Through Collaboration Study 003. *Oncologist* 2012; 17: 321.
104. Amelio JM, Rockberg J, Hernandez RK et al. Population-based study of giant cell tumor of bone in Sweden (1983–2011). *Cancer Epidemiol* 2016; 42: 82–89.
105. Behjati S, Tarpey PS, Presneau N et al. Distinct H3F3A and H3F3B driver mutations define chondroblastoma and giant cell tumor of bone. *Nat Genet* 2013; 45: 1479–1482.
106. van der Heijden L, Dijkstra PDS, Blay JY, Gelderblom H. Giant cell tumour of bone in the denosumab era. *Eur J Cancer* 2017; 77: 75–83.
107. Gouin F, Rochwerger AR, Di Marco A et al. Adjuvant treatment with zoledronic acid after extensive curettage for giant cell tumours of bone. *Eur J Cancer* 2014; 50: 2425–2431.
108. Rutkowski P, Gaston L, Borkowska A et al. Denosumab treatment of inoperable or locally advanced giant cell tumor of bone - multicenter analysis outside clinical trial. *Eur J Surg Oncol* 2018; 44: 1384–1390.
109. Chawla S, Henshaw R, Seeger L et al. Safety and efficacy of denosumab for adults and skeletally mature adolescents with giant cell tumour of bone: interim analysis of an open-label, parallel-group, phase 2 study. *Lancet Oncol* 2013; 14: 901–908.
110. Shi W, Indelicato DJ, Reith J et al. Radiotherapy in the management of giant cell tumor of bone. *Am J Clin Oncol* 2013; 36: 505–508.
111. Vujovic S, Henderson S, Presneau N et al. Brachyury, a crucial regulator of notochordal development, is a novel biomarker for chordomas. *J Pathol* 2006; 209: 157–165.
112. Rodallec MH, Feydy A, Larousserie F et al. Diagnostic imaging of solitary tumors of the spine: what to do and say. *Radiographics* 2008; 28: 1019–1041.
113. Stacchiotti S, Sommer J. Chordoma Global Consensus Group. Building a global consensus approach to chordoma: a position paper from the medical and patient community. *Lancet Oncol* 2015; 16: e71–e83.
114. DeLaney TF, Liebsch NJ, Pedlow FX et al. Long-term results of phase II study of high dose photon/proton radiotherapy in the management of spine chordomas, chondrosarcomas, and other sarcomas. *J Surg Oncol* 2014; 110: 115–122.
115. Schulz-Ertner D, Karger CP, Feuerhake A et al. Effectiveness of carbon ion radiotherapy in the treatment of skull-base chordomas. *Int J Radiat Oncol Biol Phys* 2007; 68: 449–457.
116. Stacchiotti S, Gronchi A, Fossati P et al. Best practices for the management of local-regional recurrent chordoma: a position paper by the Chordoma Global Consensus Group. *Ann Oncol* 2017; 27: 1230–1242.
117. Stacchiotti S, Longhi A, Ferraresi V et al. Phase II study of imatinib in advanced chordoma. *J Clin Oncol* 2012; 30: 914–920.



118. Bompas E, Le Cesne A, Tresch-Bruneel E et al. Sorafenib in patients with locally advanced and metastatic chordomas: a phase II trial of the French Sarcoma Group (GSF/GETO). *Ann Oncol* 2015; 26: 2168–2173.
119. Lebellec L, Chauffert B, Blay JY et al. Advanced chordoma treated by first-line molecular targeted therapies: outcomes and prognostic factors. A retrospective study of the French Sarcoma Group (GSF/GETO) and the Association des Neuro-Oncologues d'Expression Française (ANOCEF). *Eur J Cancer* 2017; 79: 119–128.
120. Gerrand C, Athanasou N, Brennan B et al. UK guidelines for the management of bone sarcomas. *Clin Sarcoma Res* 2016; 6: 7.
121. Brewster DH, Clark D, Hopkins L et al. Subsequent hospitalisation experience of 5-year survivors of childhood, adolescent, and young adult cancer in Scotland: a population based, retrospective cohort study. *Br J Cancer* 2014; 110: 1342–1350.
122. Henson KE, Reulen RC, Winter DL et al. Cardiac mortality among 200 000 five-year survivors of cancer diagnosed at 15 to 39 years of age: the teenage and young adult cancer survivor study. *Circulation* 2016; 134: 1519.
123. Dykewicz CA. Summary of the guidelines for preventing opportunistic infections among hematopoietic stem cell transplant recipients. *Clin Infect Dis* 2001; 33: 139–144.